

Imaging Iron in MS using Susceptibility Weighted Imaging (SWI): “Is the basic etiology of multiple sclerosis vascular in origin?”

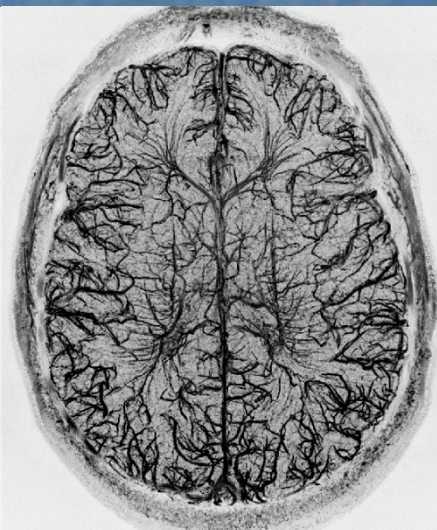E. Mark Haacke

Wayne State University

Detroit, Michigan 48201 and

The MRI Institute for Biomedical Research

Detroit, Michigan 48202



Outline

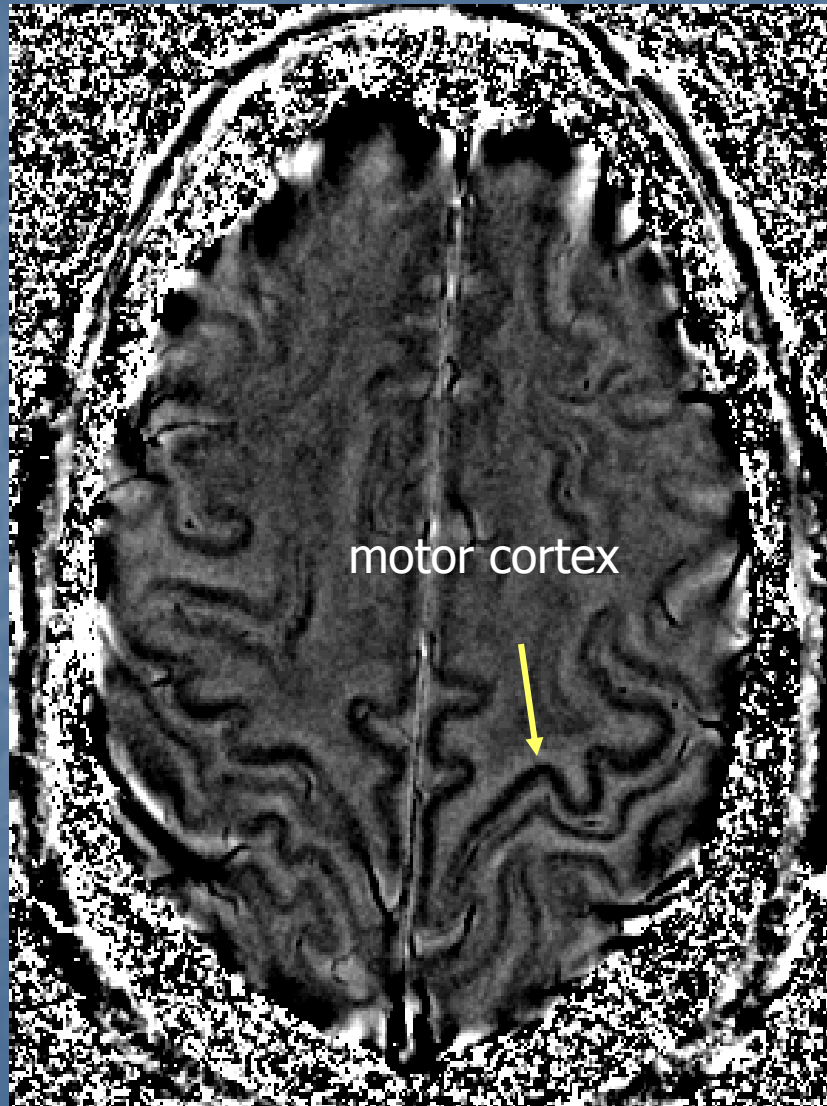
- Normal iron content in the brain
- Local iron increases in MS
- Proving it is iron we are seeing
- Iron in MS lesions
- Iron in vessel wall
- SWIM and deoxyhemoglobin
- Reduced perfusion in MS
- Iron increases in the central venous drainage system
- The link to chronic cerebrospinal venous insufficiency

Imaging Iron in Healthy Tissue

Under normal circumstances iron will appear as ferritin or heme-iron in the form of deoxyhemoglobin



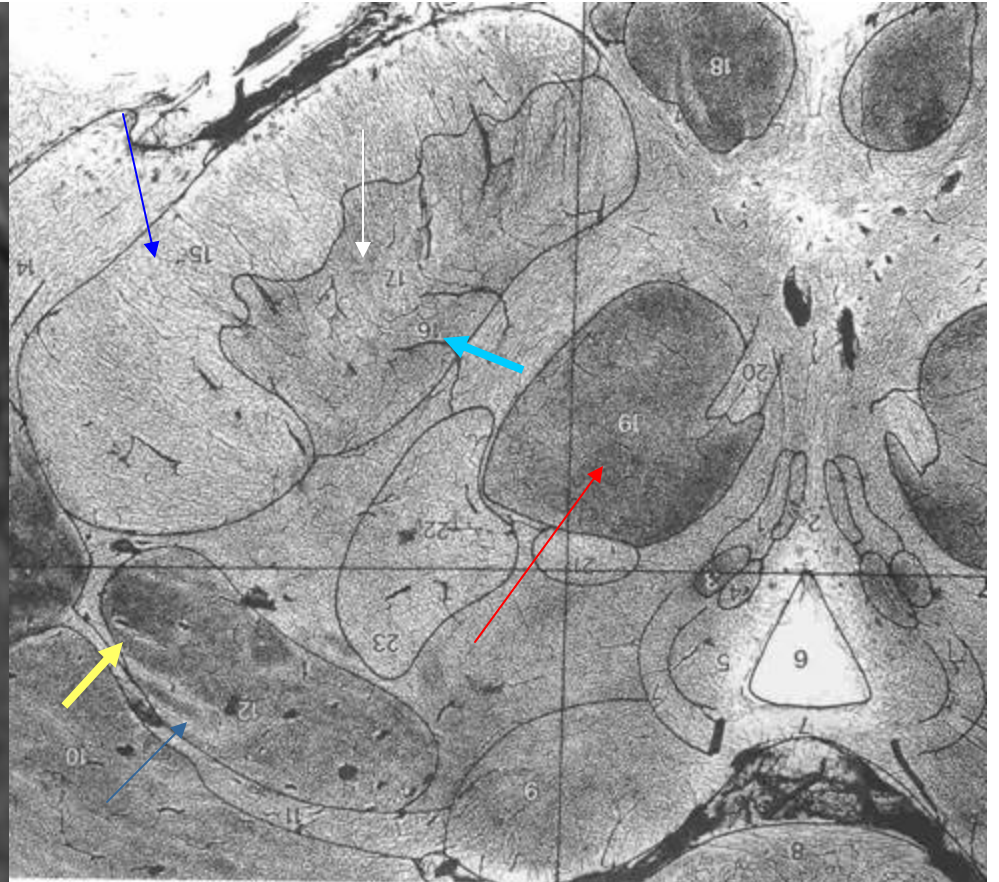
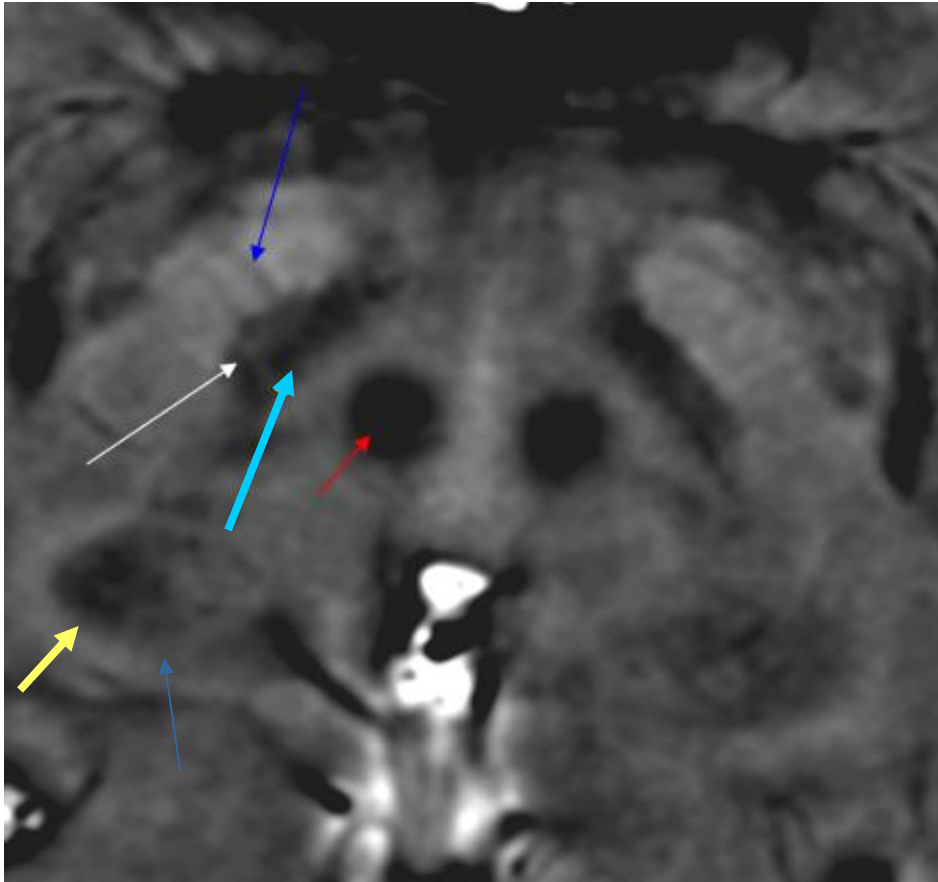
Iron can be visualized with SWI



Demonstration of ferritin iron distribution in the brain.

The difference between white matter, gray matter and CSF creates a new type of iron related contrast with SWI.

Note the highest iron concentration in the motor cortex.



—→ Crus Cerebri
 —→ Medial Geniculate

—→ Red Nucleus
 —→ Substantia Nigra
 —→ Pars compacta
 —→ Pars reticulata

Imaging Iron in Diseased Tissue

Local iron increases
seen in the basal
ganglia and thalamus
for multiple sclerosis
It is likely to be either
ferritin or hemosiderin

Iron in Multiple Sclerosis

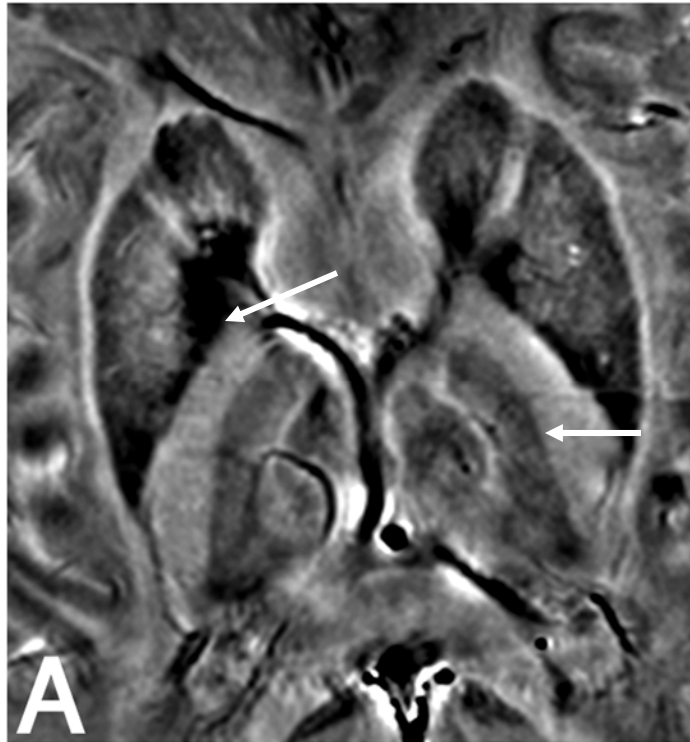
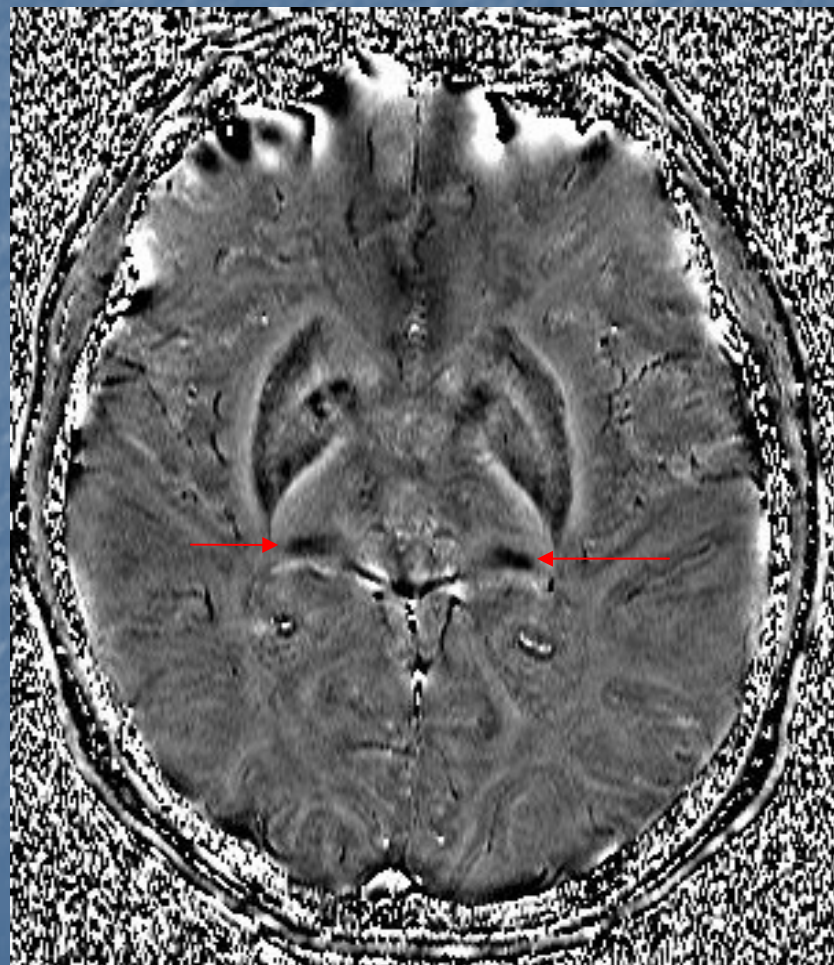


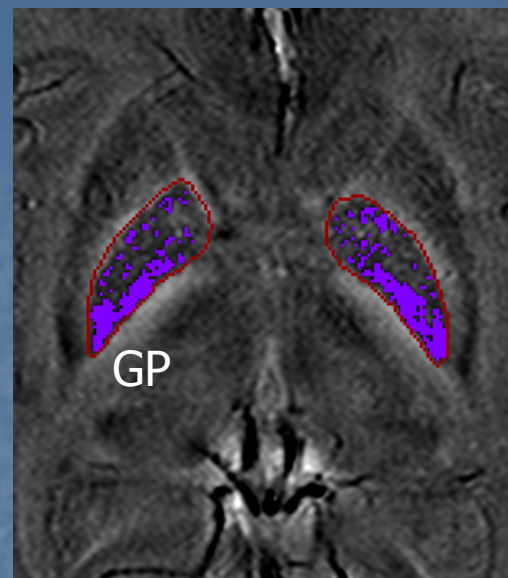
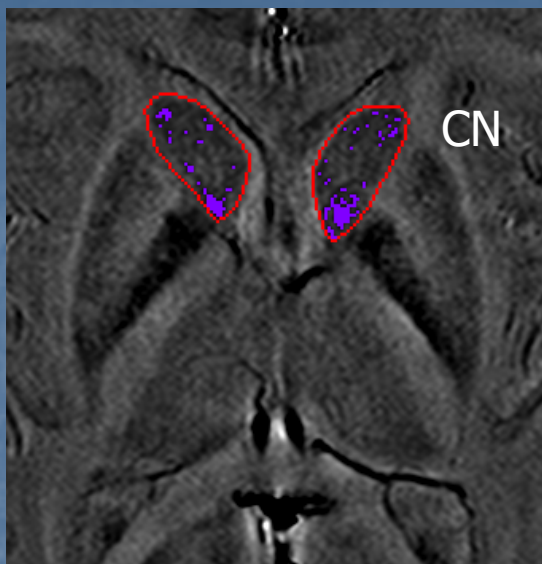
Figure A is from 10-10-2006

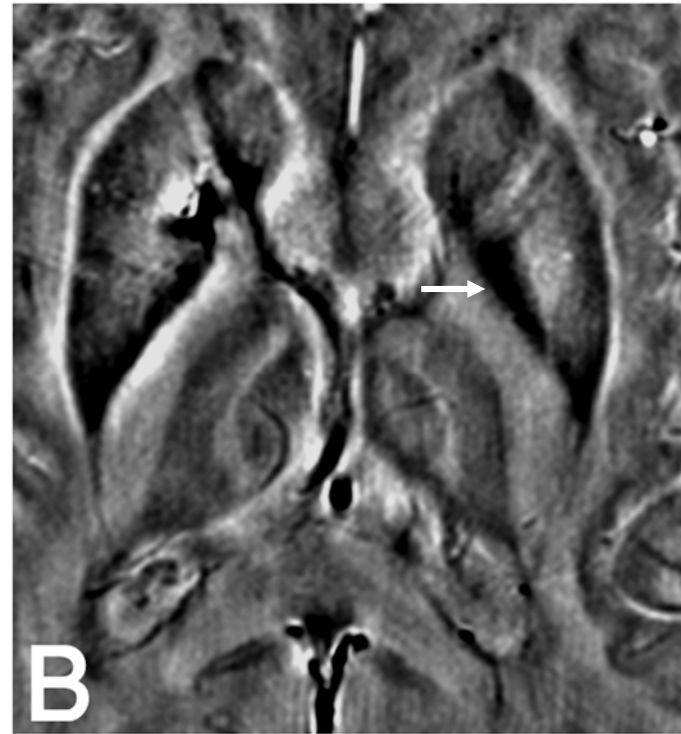

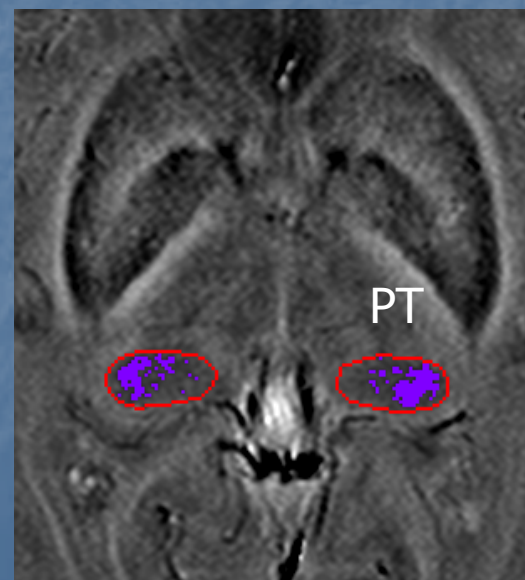
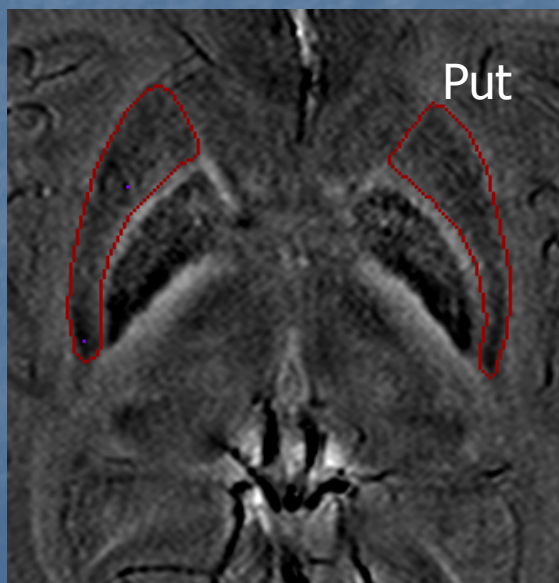Figure B is from 3-25-2008

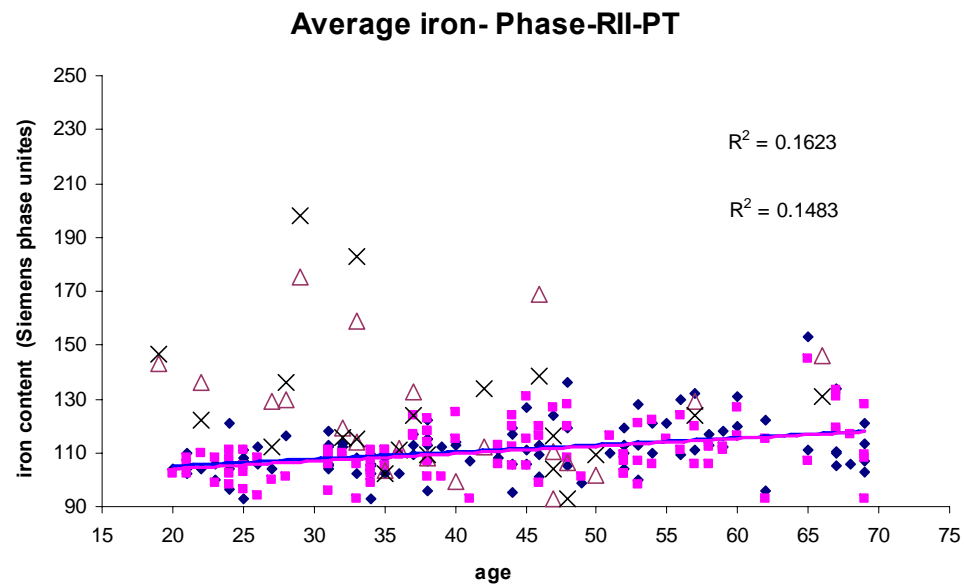
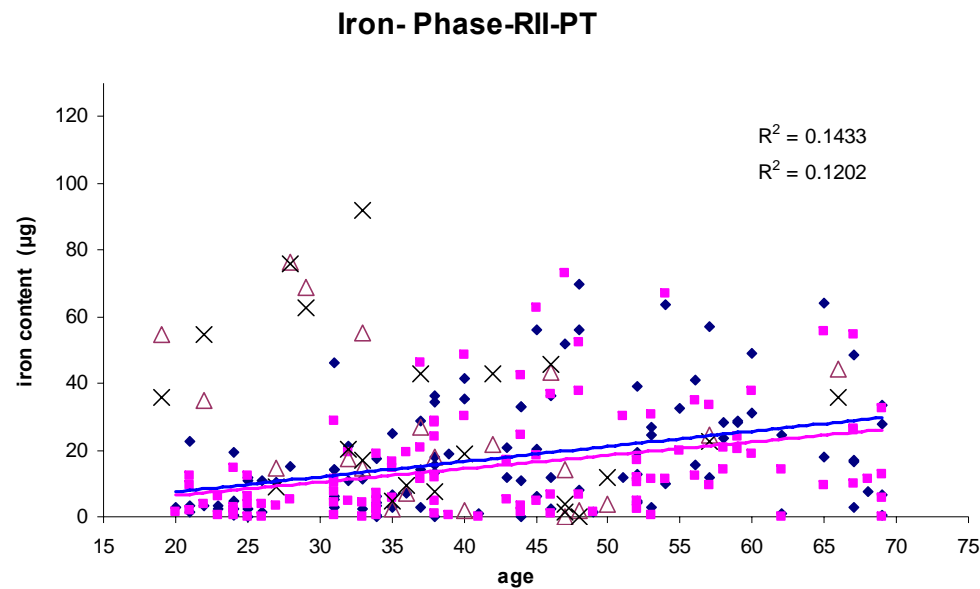
Iron in pulvinar thalamus



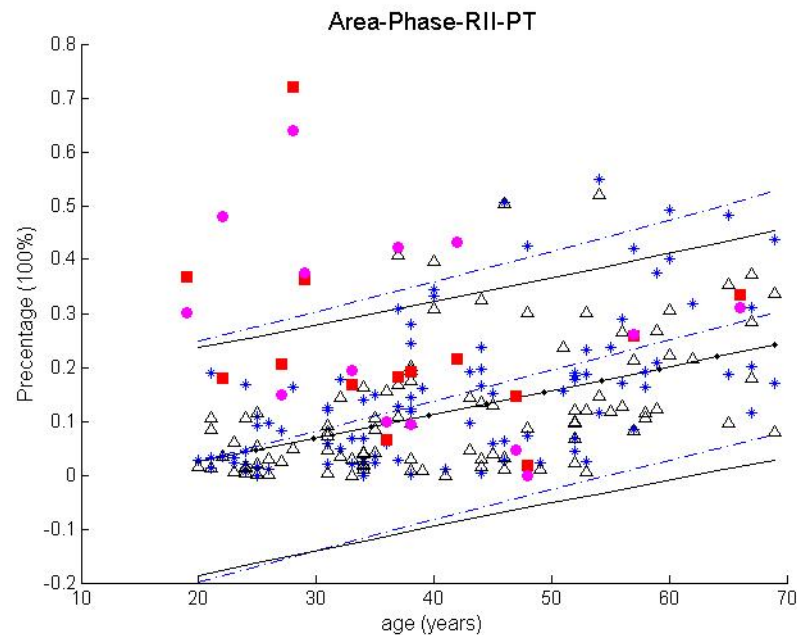


Blue areas represent region II: the high iron content region

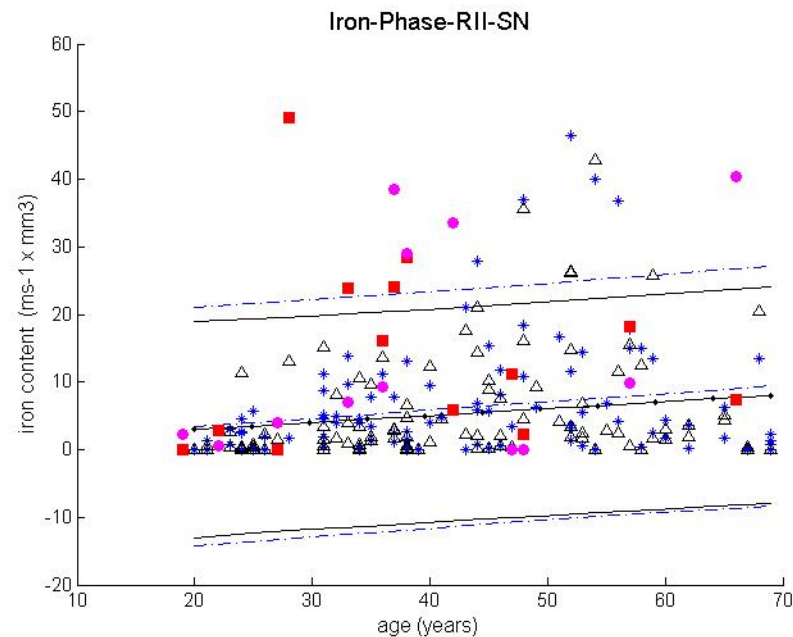




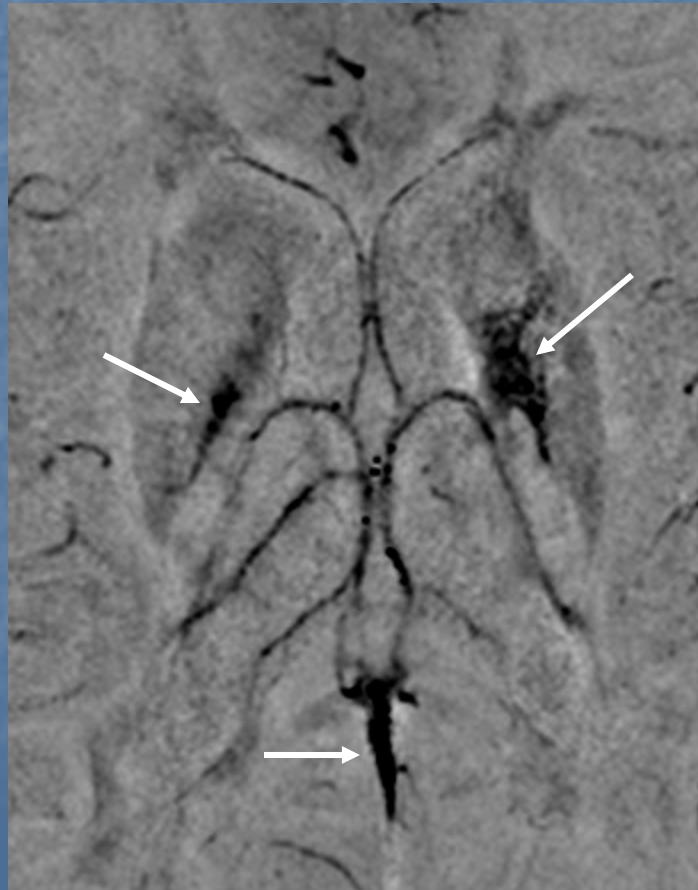
SWI putative iron content as measured with high pass filtered phase data shows a clear iron increase in younger subjects compared to age matched normals.



SWI putative iron content as measured with high pass filtered phase data shows a clear iron increase in younger subjects compared to age matched normals.



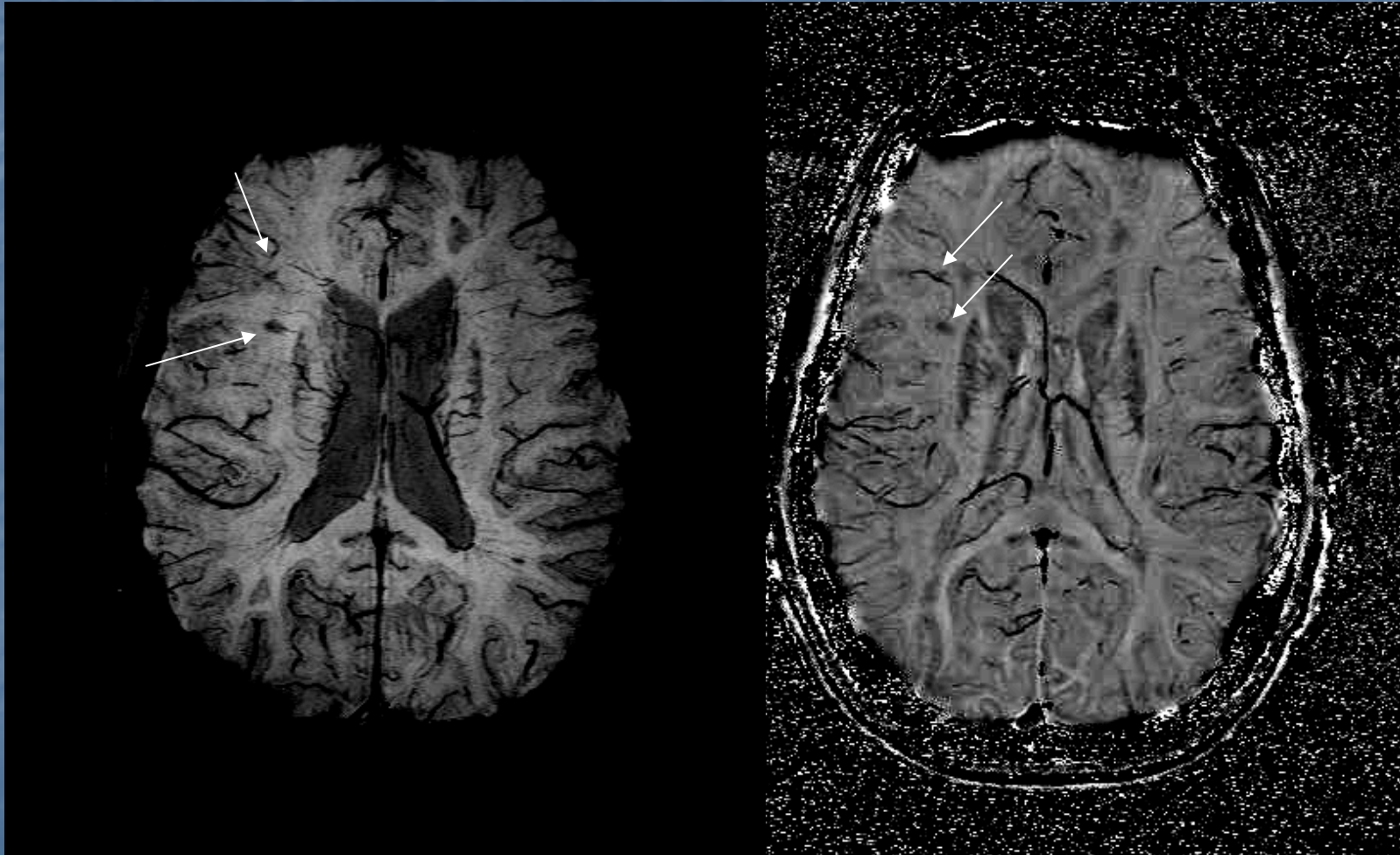
Iron in the globus pallidus bilaterally. Far above normal levels. Is the great vein of Galen also showing an increase in deoxyhemoglobin?



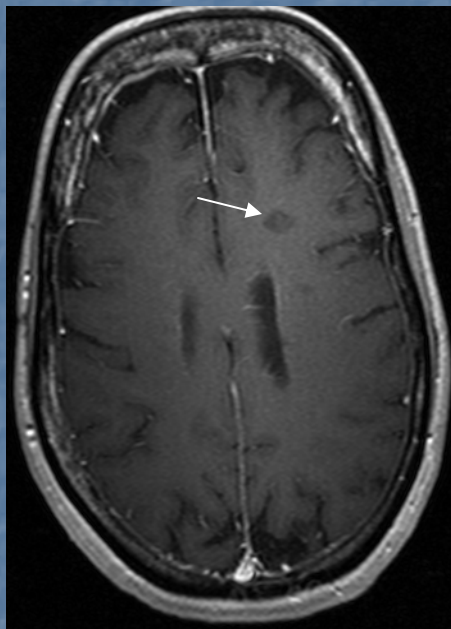
Iron in lesions

We see iron not only in the basal ganglia and thalamus but also in the lesions as well.

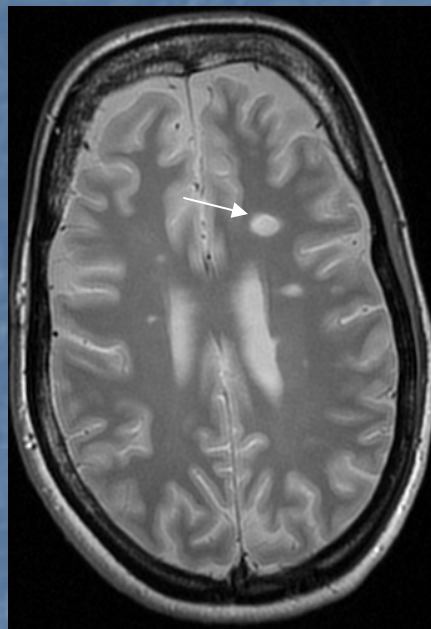
This is a classic example of a Dawson finger with this ovoid lesion containing rather uniform iron content.



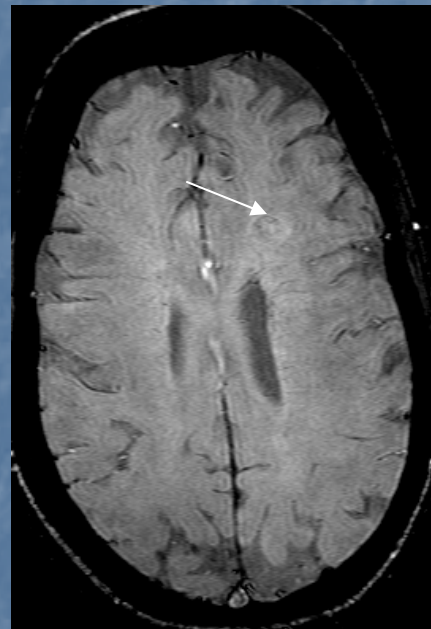
Central iron surrounded by another iron ring structure



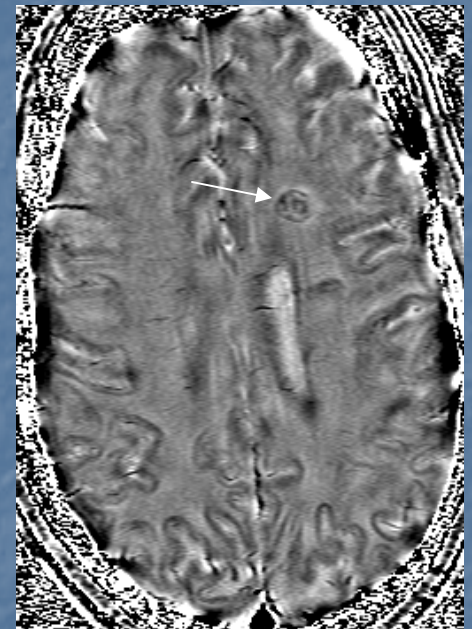
T1 Post



T2



SWI Pre Magnitude



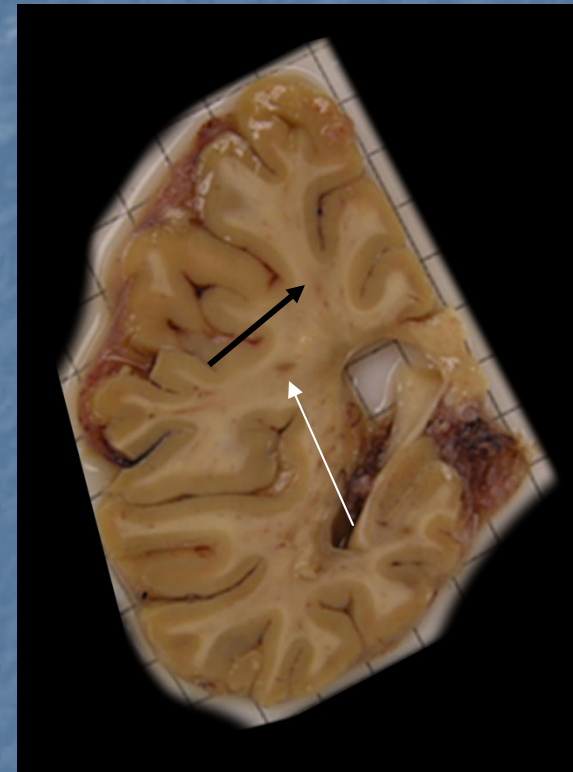
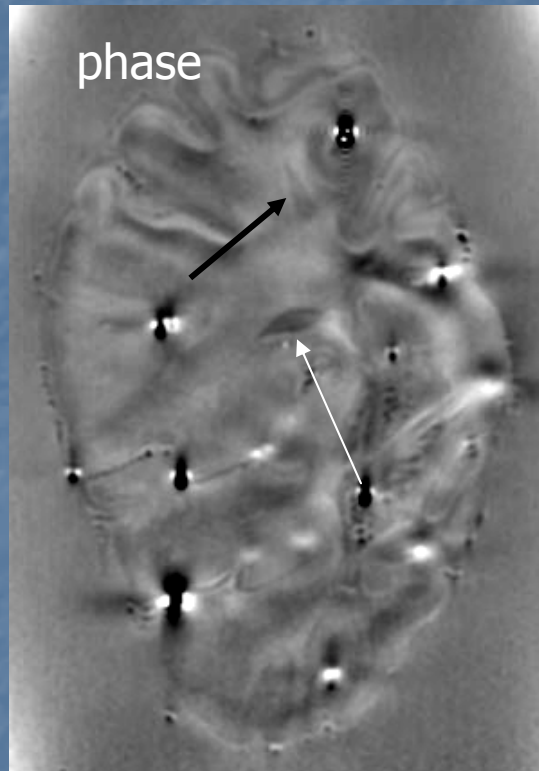
SWI Pre Phase

Validating that the SWI filtered phase really does represent local iron content

We use SR-XRF or synchrotron radiation x-ray fluorescence to compare to SWI phase but one can also use a Perl's stain to find iron.

SWI-0.5x0.5x0.5 mm³

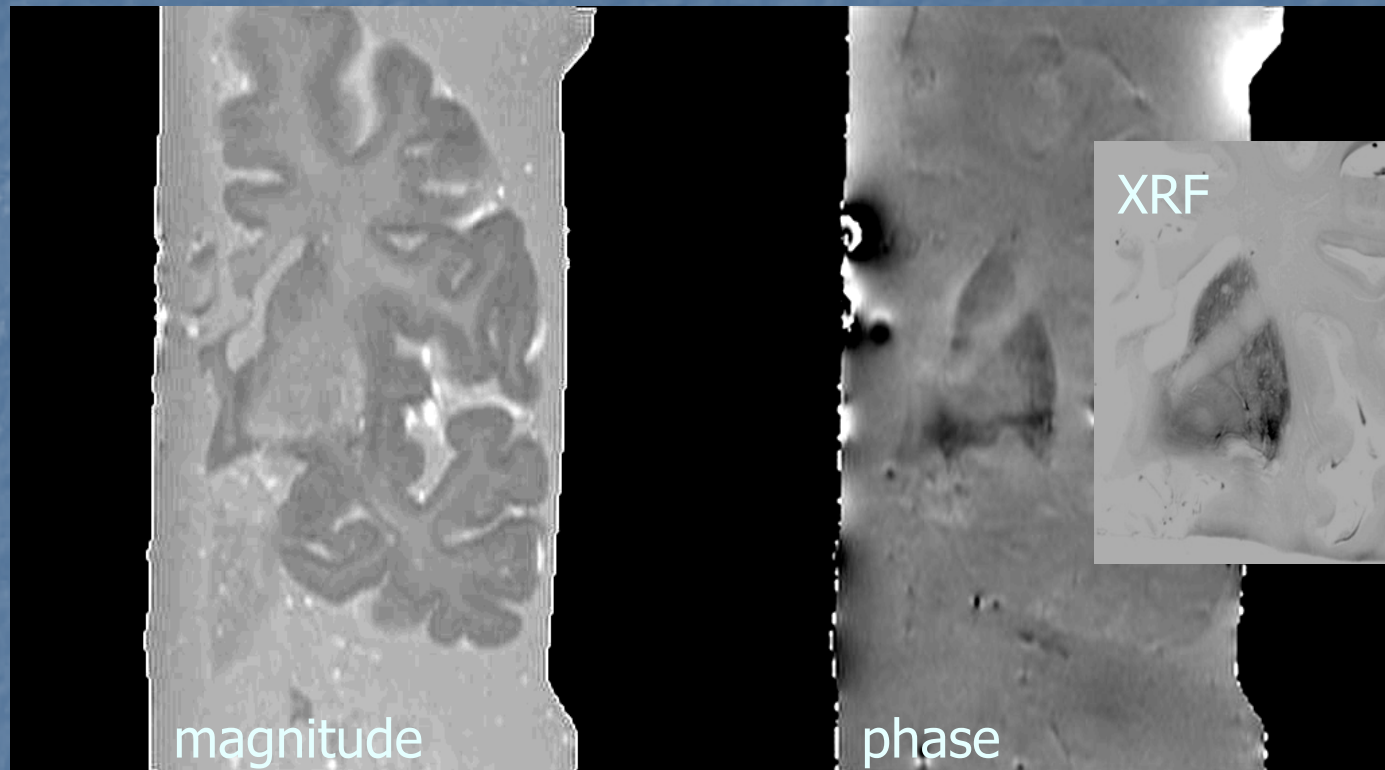
- TR=29ms
- TE=7.02ms
- FA=12°
- BW=50Hz/pix



Two MS lesions seen within the slab using 3D SWI.

Collaborative research with SWI and XRF with Helen Nichol from the University of Saskatchewan in Saskatoon.

SWI and XRF scanning



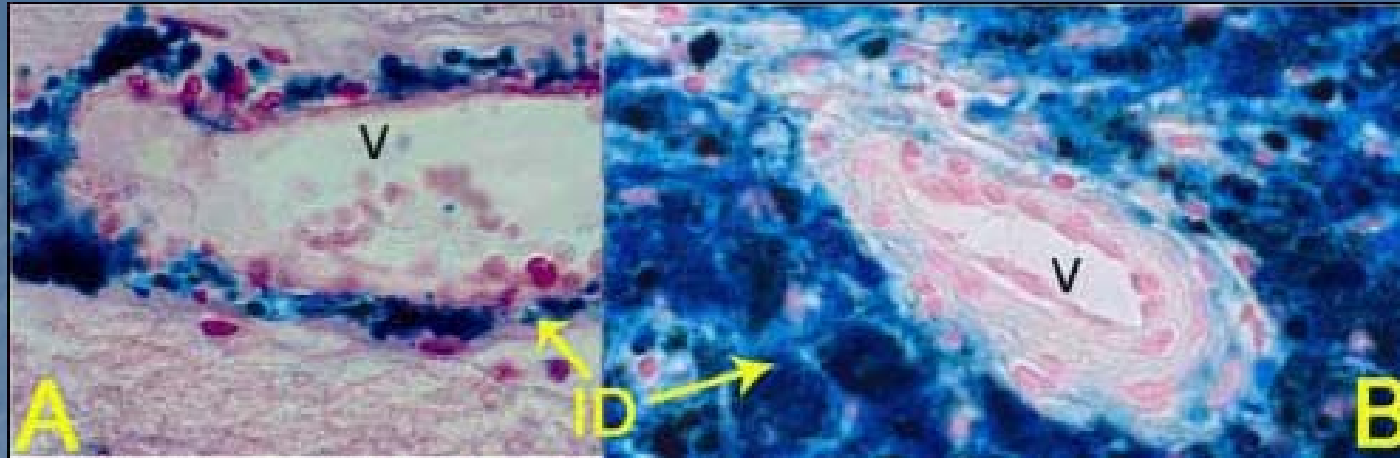
susceptibility weighted imaging: 500 μ resolution

x-ray fluorescence imaging: 50 μ resolution

images courtesy of: Helen Nichol and Richard McCrea

Dept of Anatomy and Cell Biology, University of Saskatchewan.

Perhaps the iron seen with SWI in MS is hemosiderin?



Panel A, intra and extra-cellular iron deposits (ID) encircle a dilated vein (V) in a cerebral MS plaque, Perls' method 150 x.

Panel B, intra and extra-cellular iron deposits (ID) encircle a dilated vein (V) in venous ulcer bed, Perls' method 80 x

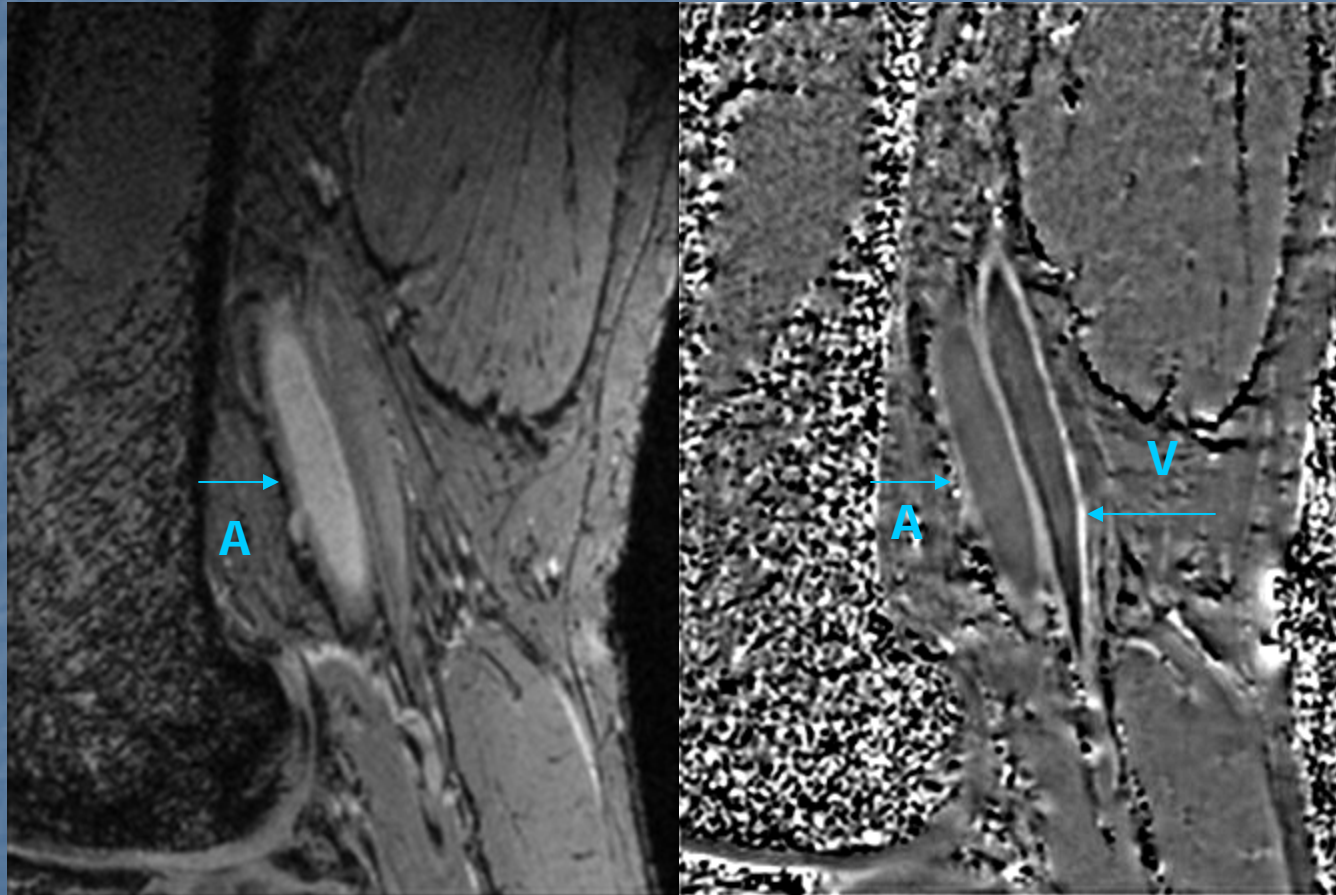
P. Zamboni, The Big Idea: Iron-dependent inflammation in venous disease and proposed parallels in multiple sclerosis.

J. Royal Society of Medicine, V99, Nov 2006 pages 589-593.

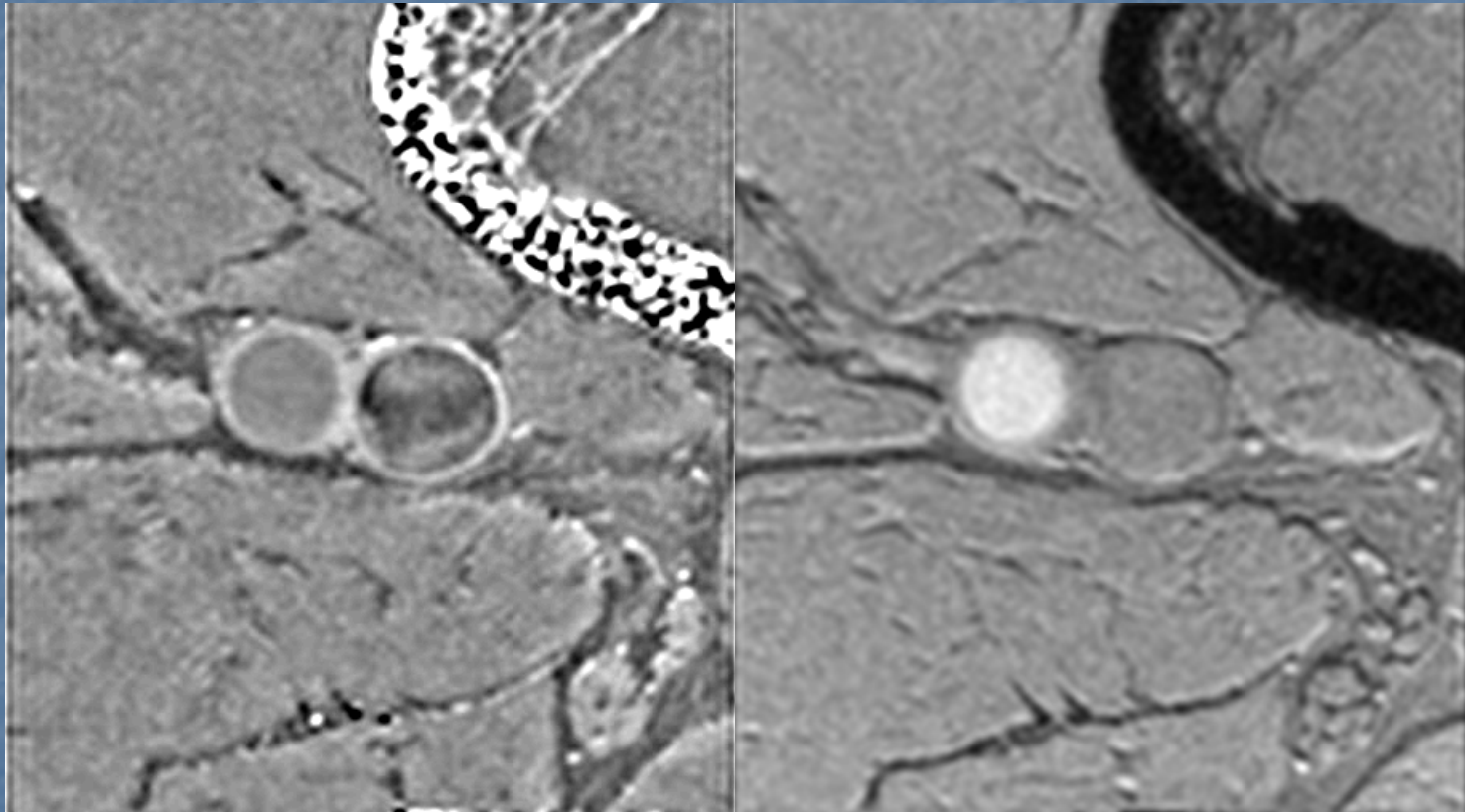
Imaging Vessel Wall

Abnormal fluid dynamics leads to an inflammatory response and atherosclerosis or a breakdown of the vessel wall for CVD.

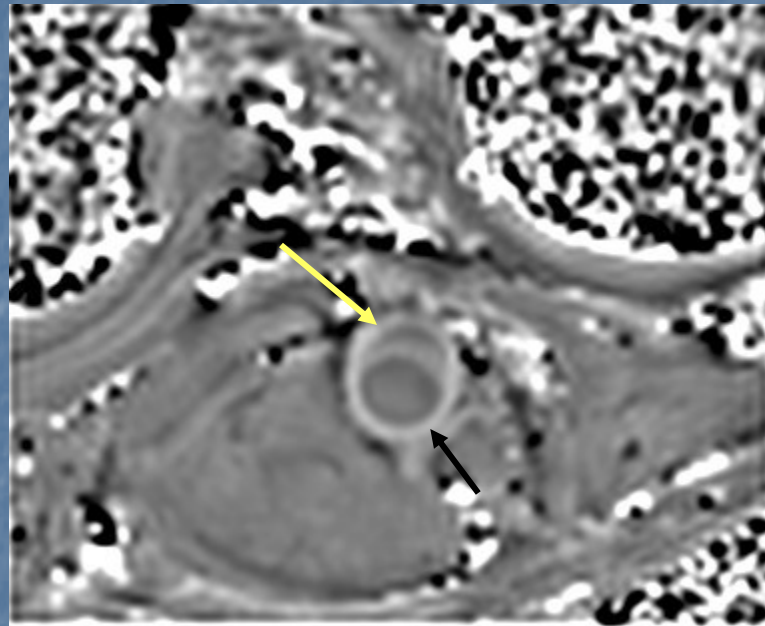
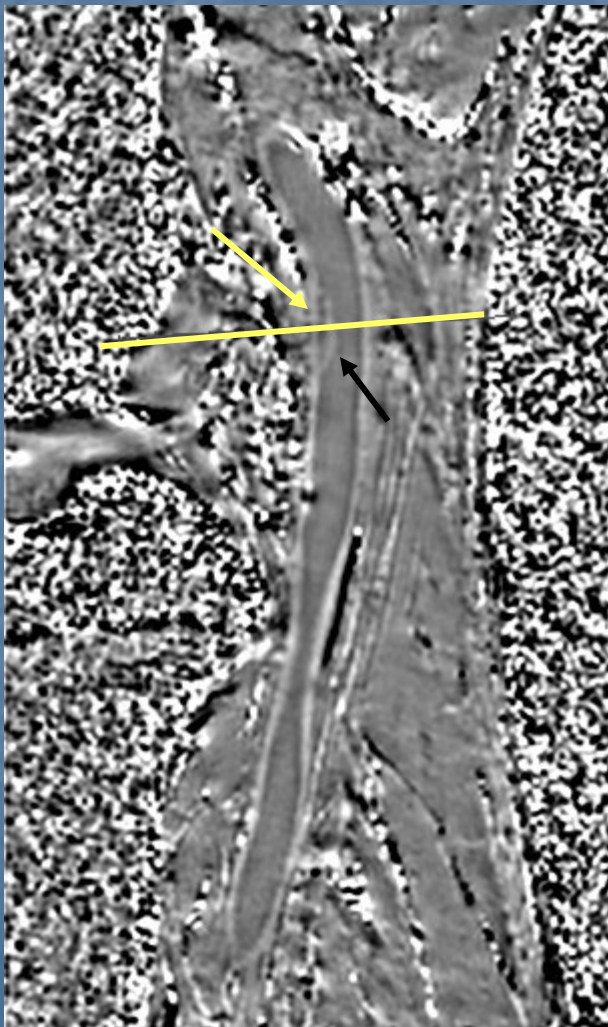
vessel wall is diamagnetic in SWI



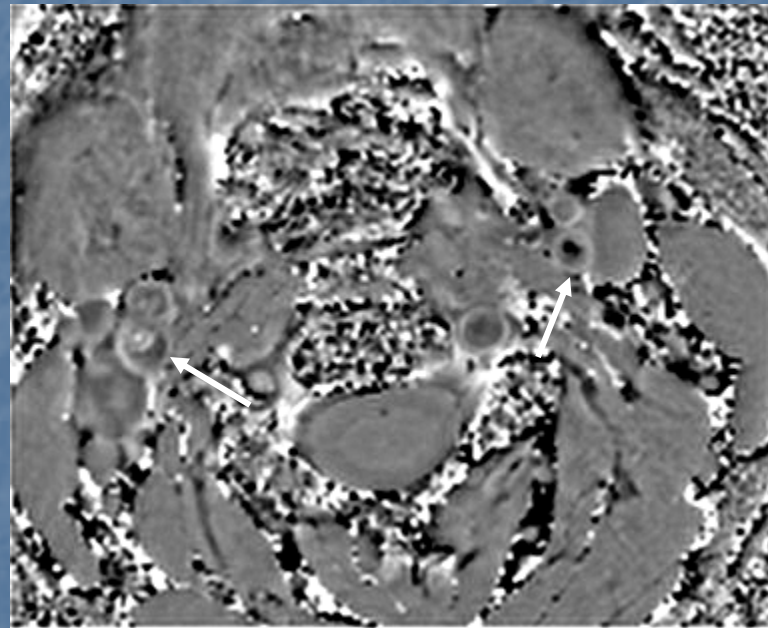
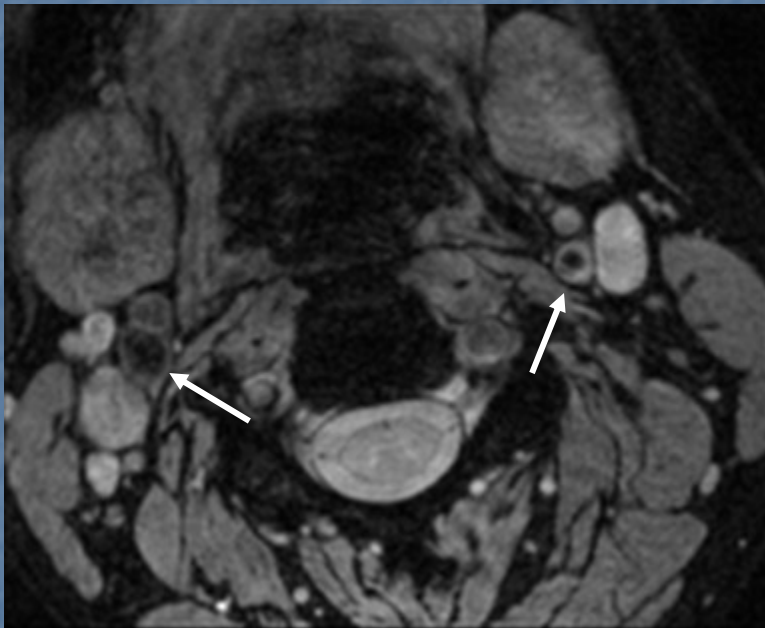
SWI transverse vessel wall



vessel wall imaging with SWI



A 25 year old female with **carotid arteritis**, the lumen of the carotid almost disappeared, and the centre dark area in the phase images could be the thrombosis.



note the details even in the area where the bifurcation is occurring
the internal carotid seems to have plaque build up on both sides
note the detail inside the right carotid and see the other slides too

Imaging Heme Iron or Deoxyhemoglobin

From this perspective SWI might be called an enhanced resting state BOLD (blood oxygen level dependent) method.

4T SWI

0.5 x 0.5 x 1.0 mm³
image from WSU

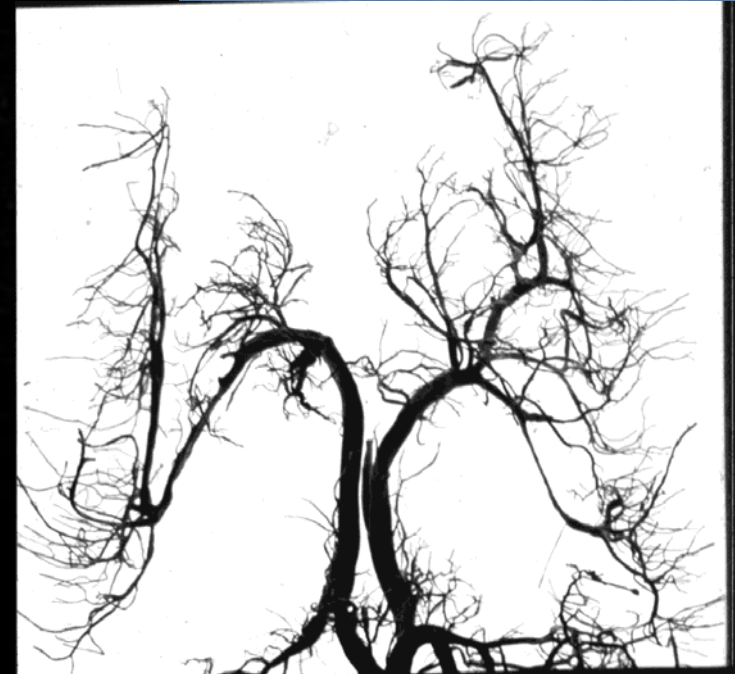
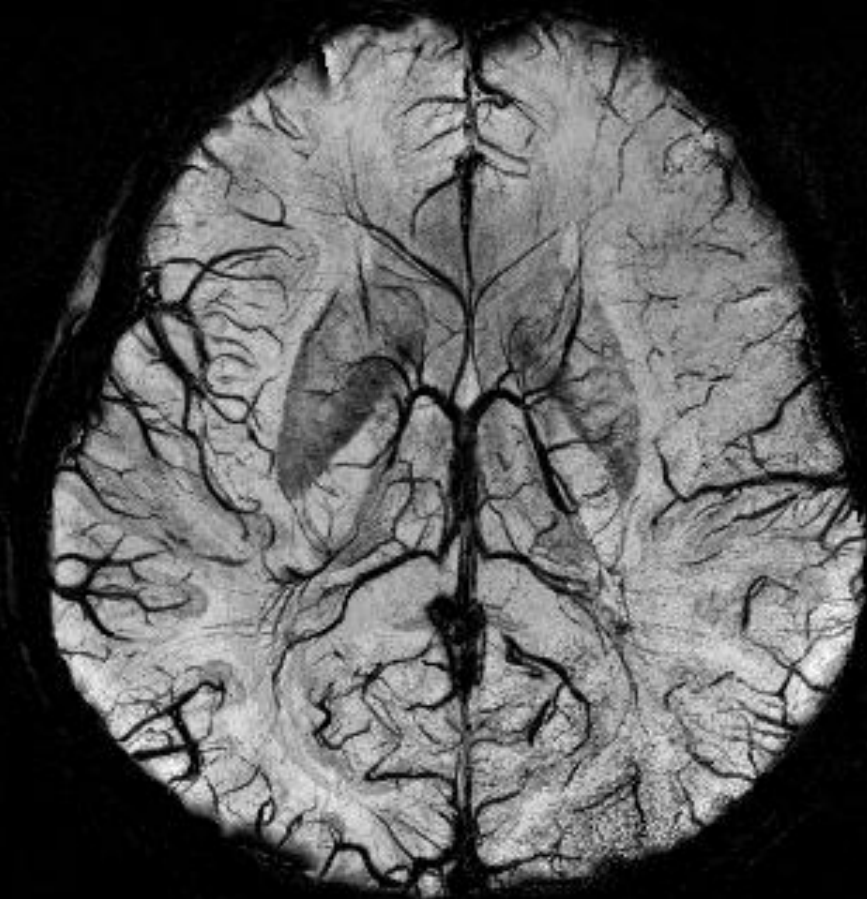
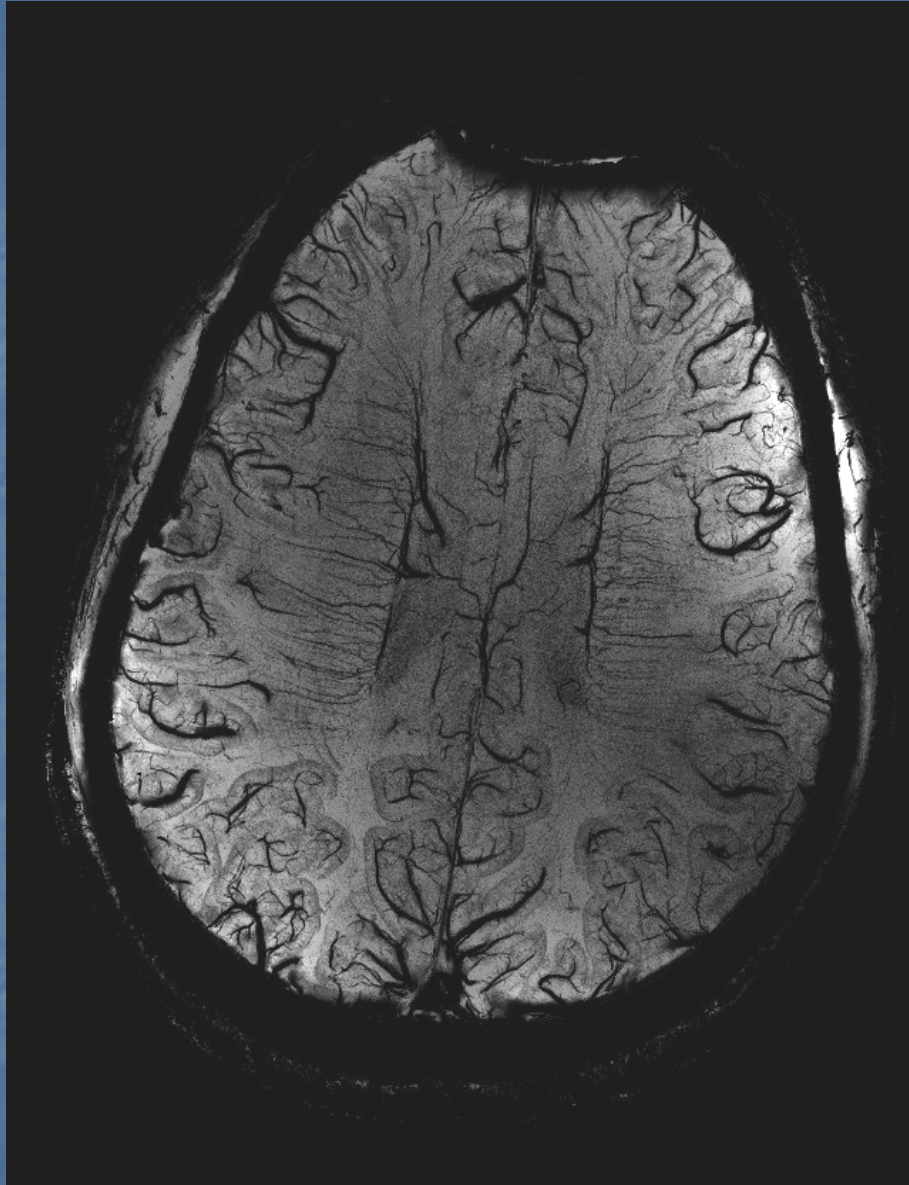


Image courtesy of
Georges Saloman

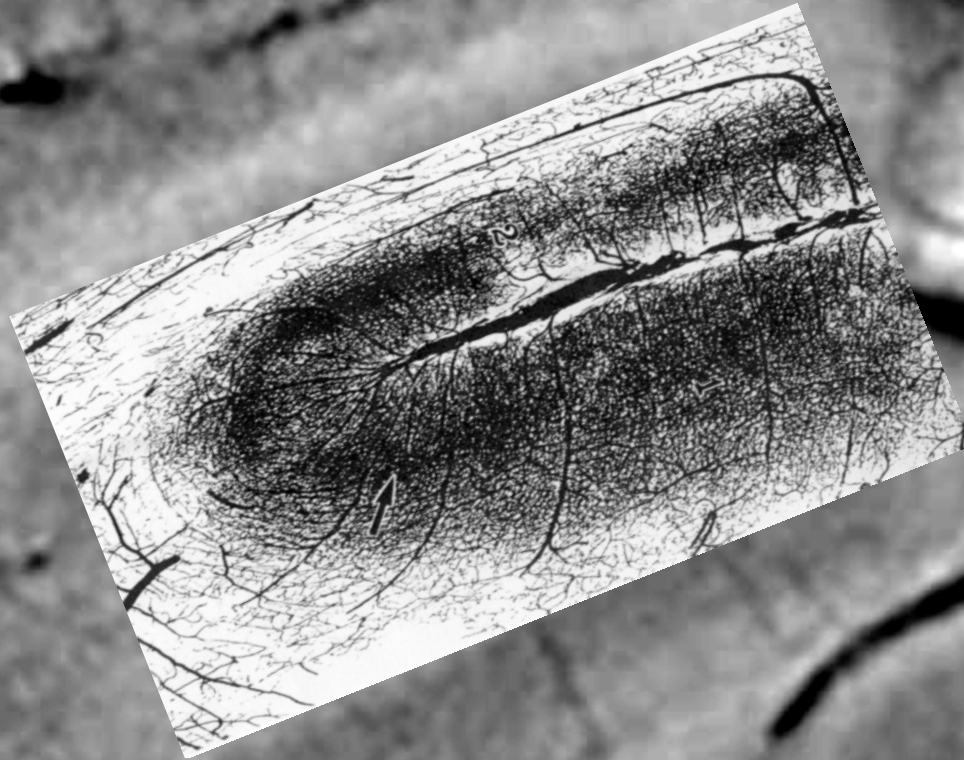

SWI is a technique that is sensitive to local iron content.

SWI at 3T projected over roughly 16 mm to show the pial and medullary veins in the brain.

SWI is very sensitive to iron in the form of deoxyhemoglobin, ferritin and hemosiderin.

7T
in vivo
visualization of
the venules



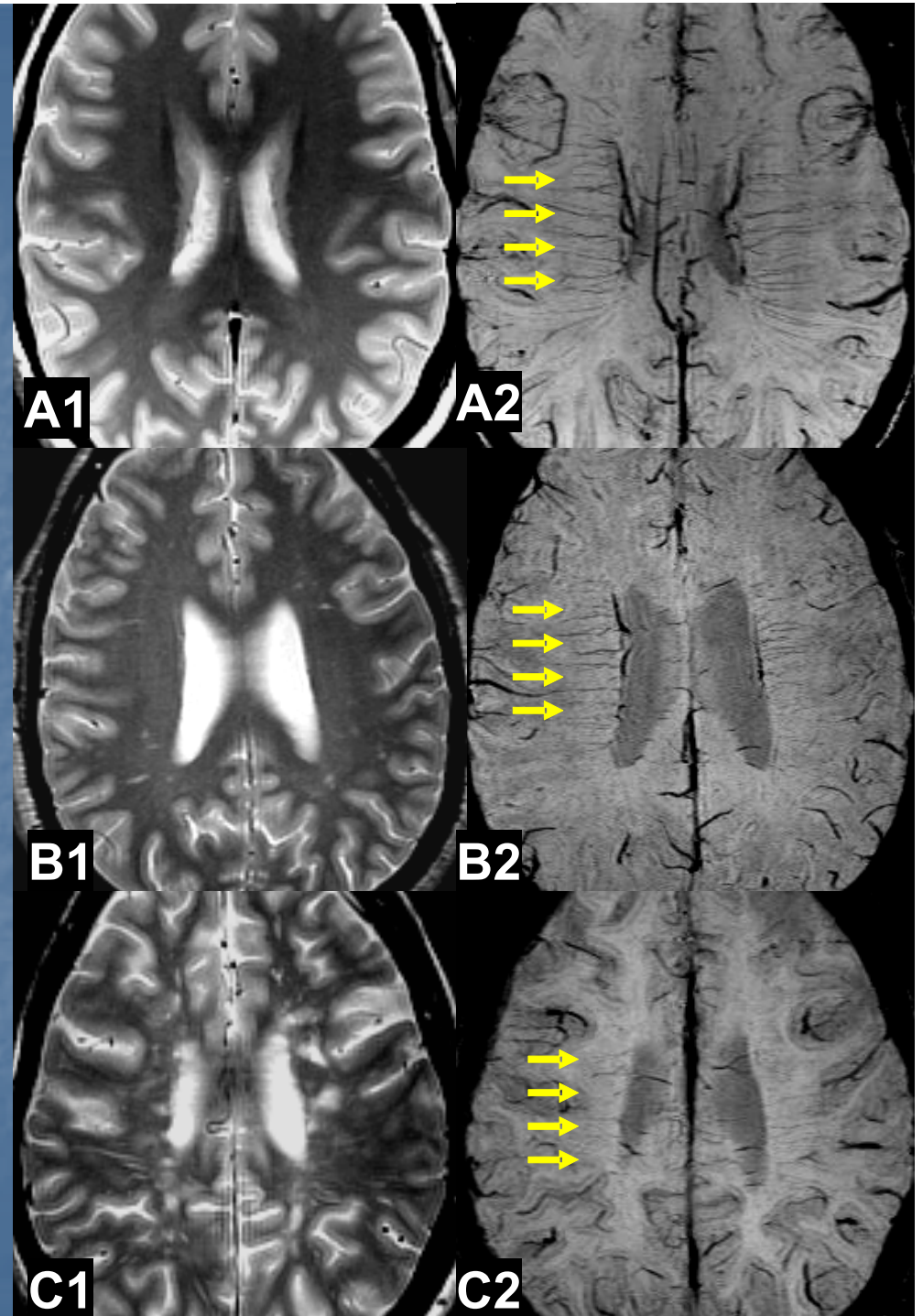
SWI Venography

normal control (A) and two MS patients (B, C) demonstrate a significantly reduced number of veins in periventricular NAWM in patients compared to controls. MS patient with more lesions (C) has less venous structures depicted on SWI mIP image than MS patient with fewer lesions (B).

Discussion: From PET data it is known that there is less oxygen utilization by white matter under MS stress. This seems to match what we see in SWI venography with the vessels most likely not showing because of the decreased levels of deoxyhemoglobin.

Do vessels degrade because flow is shunted away from them?

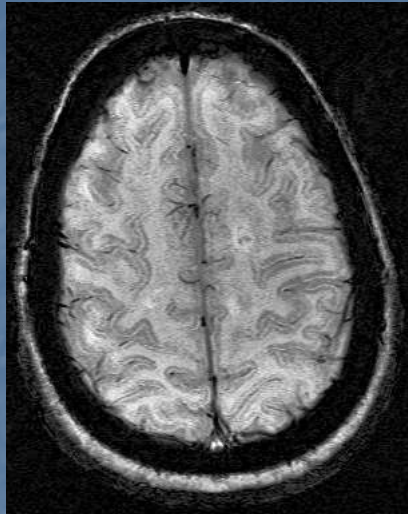
Slide courtesy of Yulin Ge, NYU



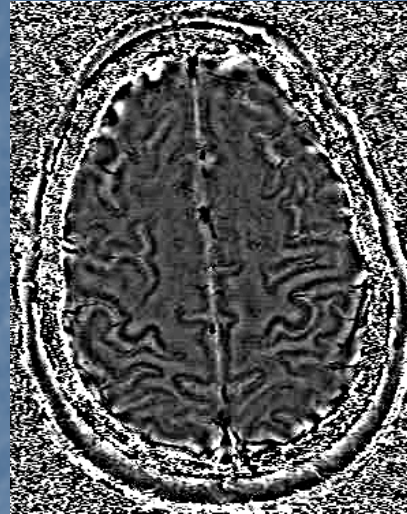
Imaging Cerebral Hemodynamics

Cerebral blood volume and blood flow and oxygen saturation are key to understanding local vascular changes.

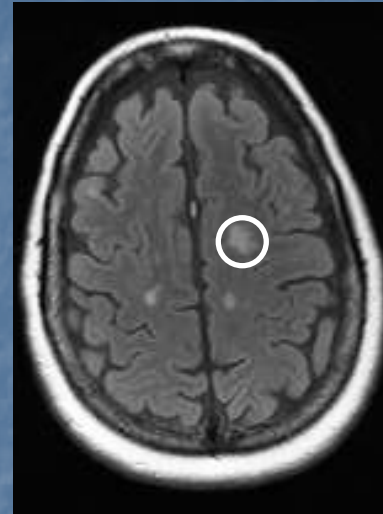
PWI shows loss of CBV in chronic lesion



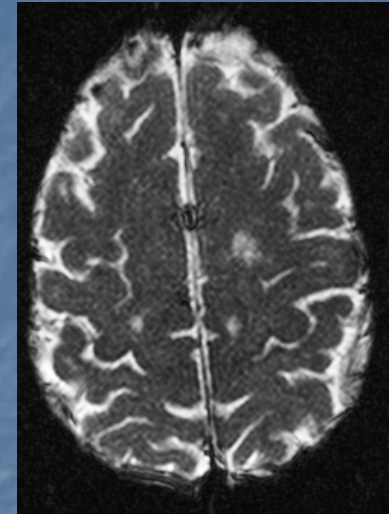
mIP (2)



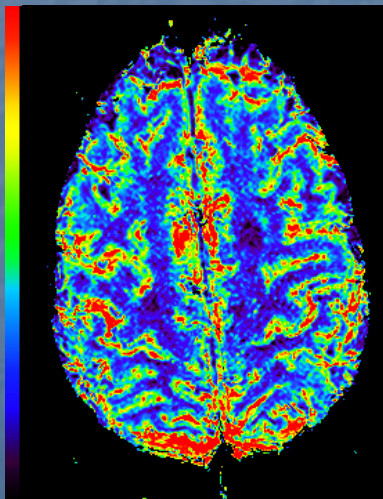
Phase



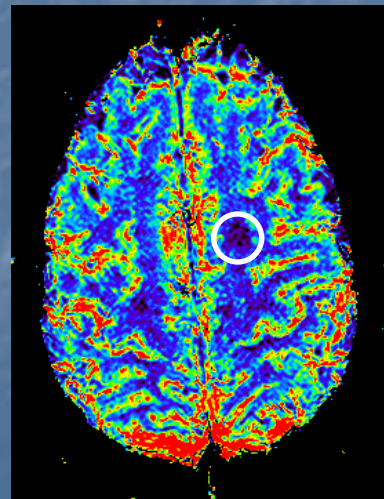
FLAIR



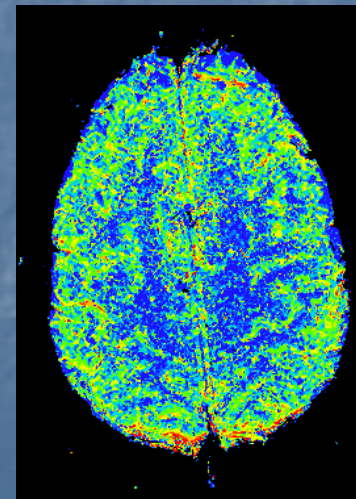
PWI



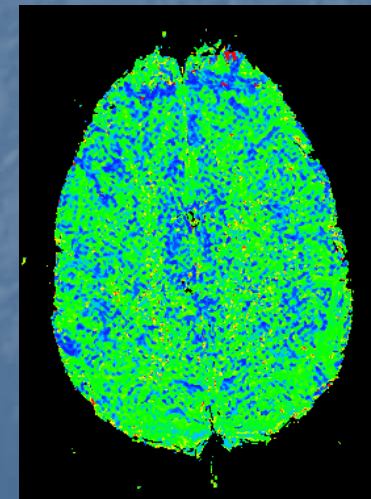
CBF



CBV

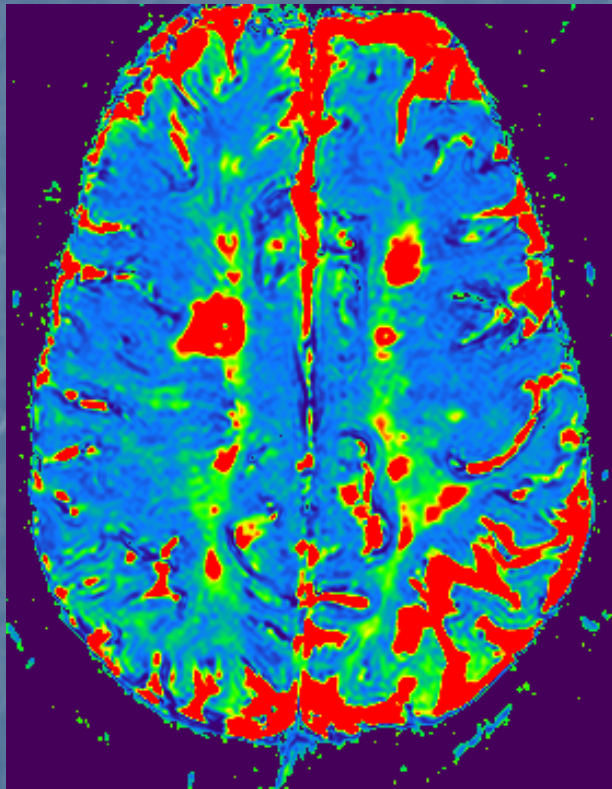


FWHM

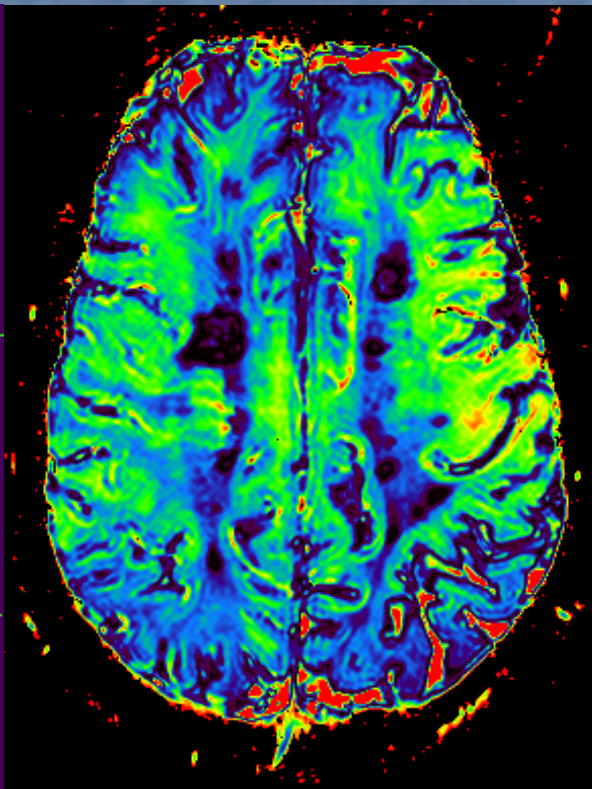


MTT

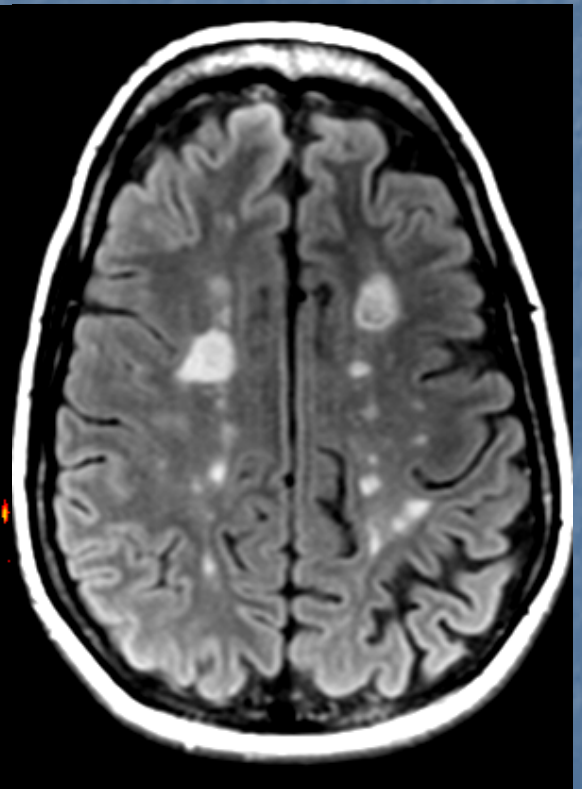
Nulling different tissues



Similarity Map: nulling veins



nulling lesions

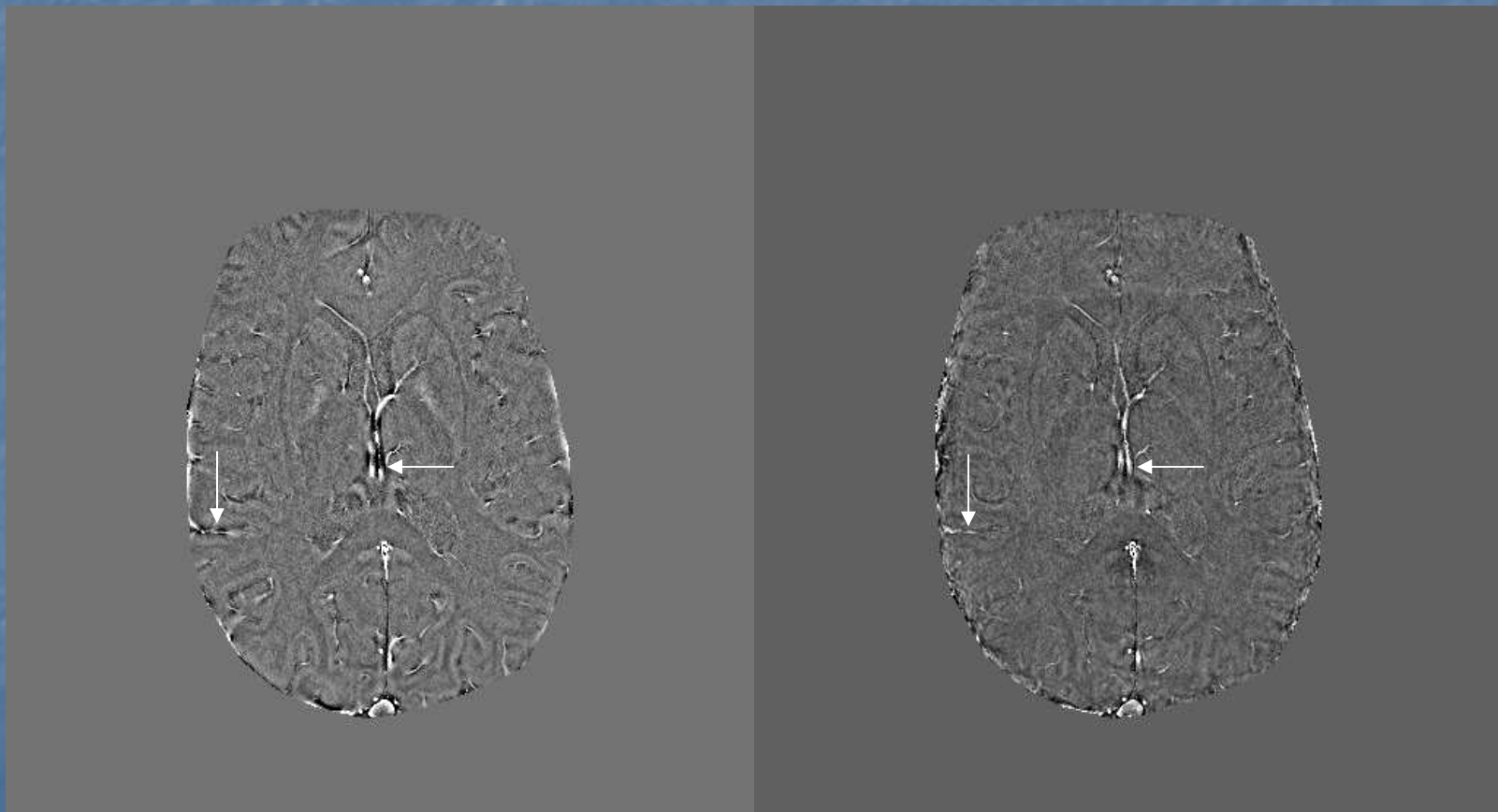


FLAIR

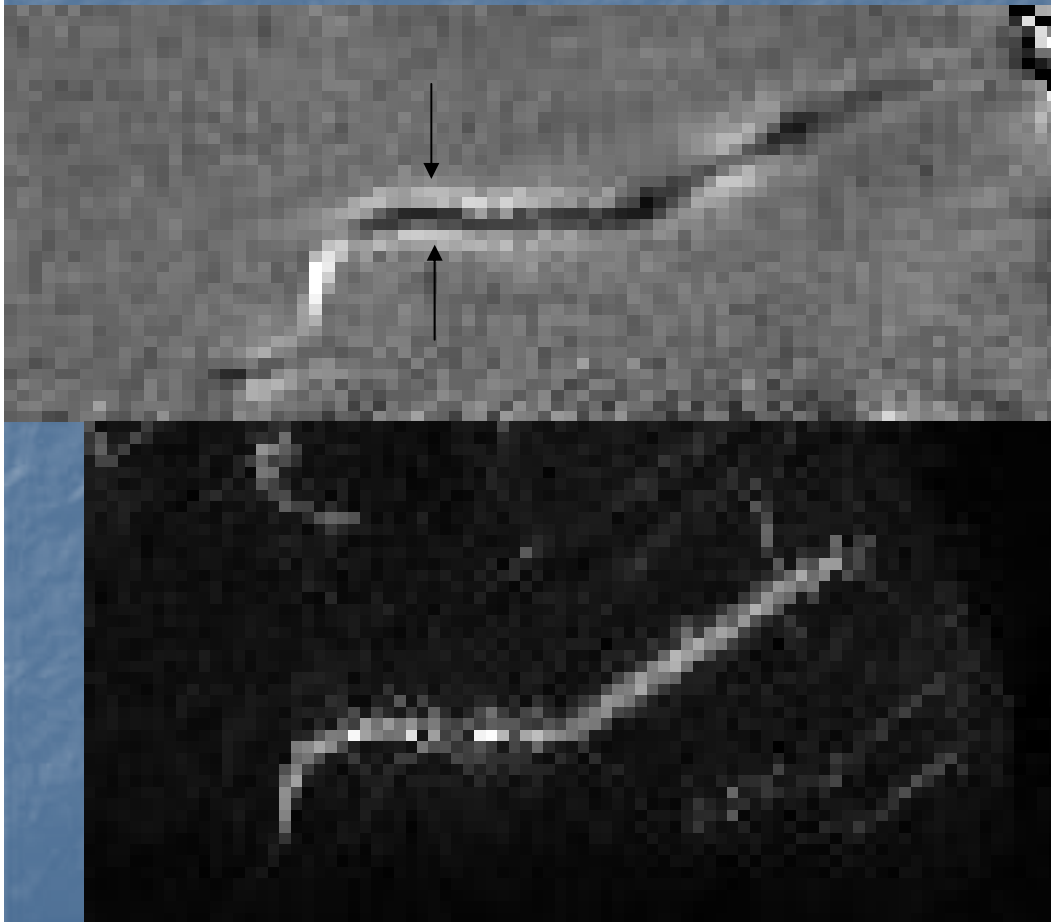
Imaging Oxygen Saturation

Finding the oxygen saturation is key to understanding local hemodynamics. We use SWIM to quantify deoxyhemoglobin.

Removing dipole artifacts



SWIM puts the magnetic field response back into the source

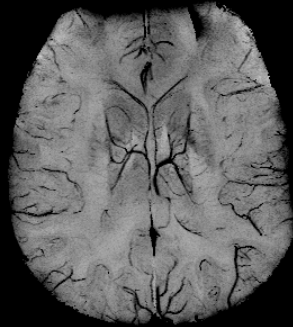


Usual phase
showing dipole field
from 0.5 mm
isotropic 3D data set

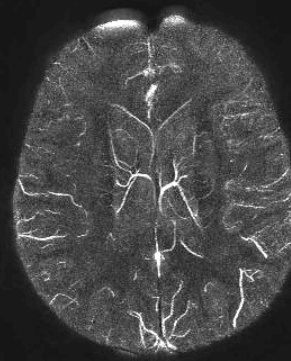
SWIM susceptibility
map of the same
region MIPped over
several slices

SWIM from three different echo times.

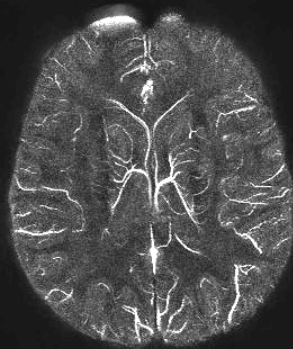TE = 19ms mIP
over phase



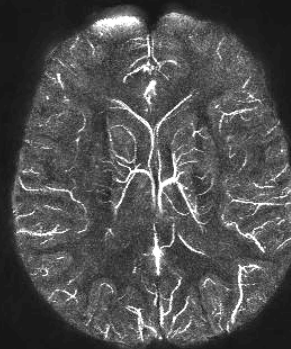
TE = 11ms



TE = 15ms



TE = 19ms

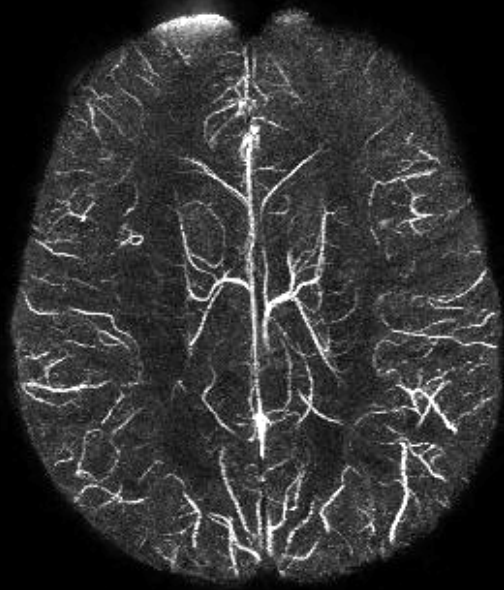

SWIM full brain analysis:

a first attempt to quantify oxygen saturation
of the veins in the brain

SWIM

TE = 19ms

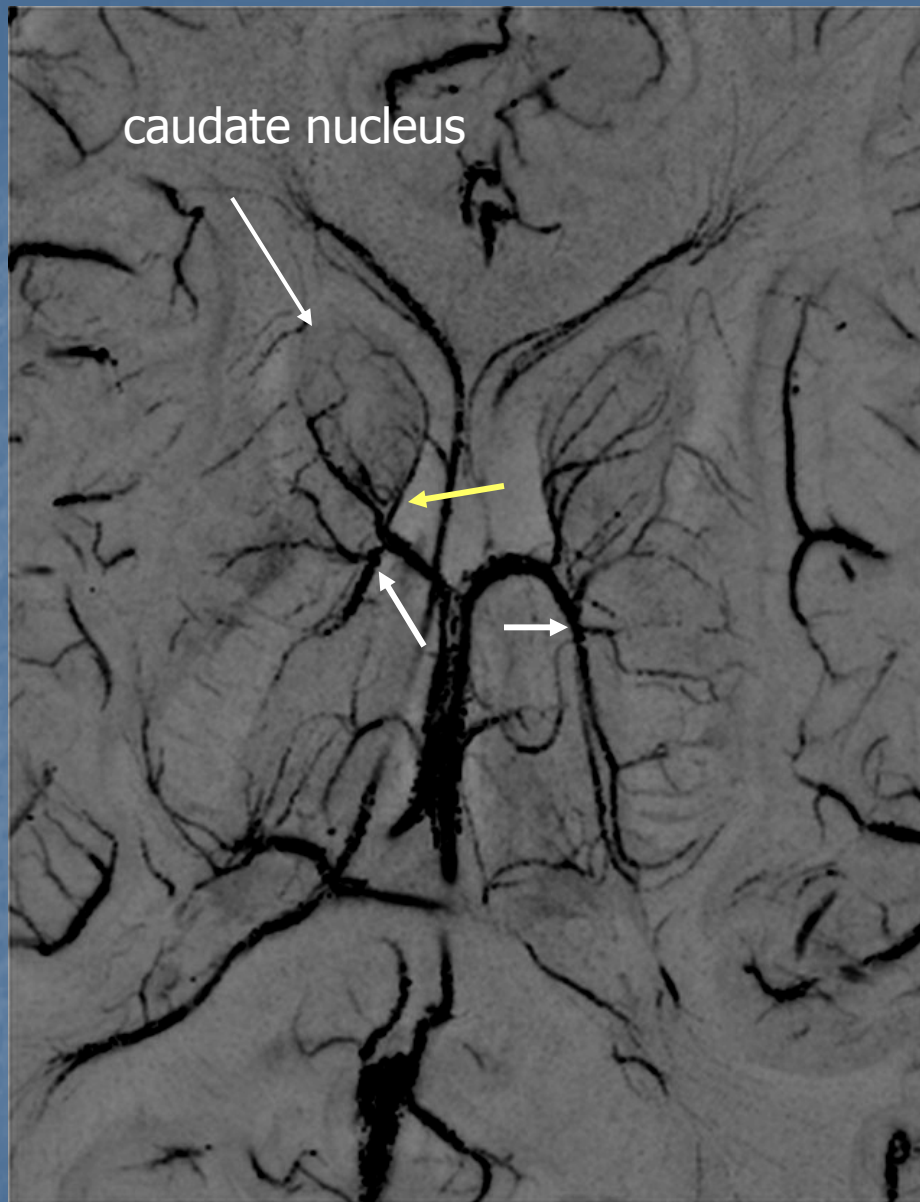

Applications of SWIM

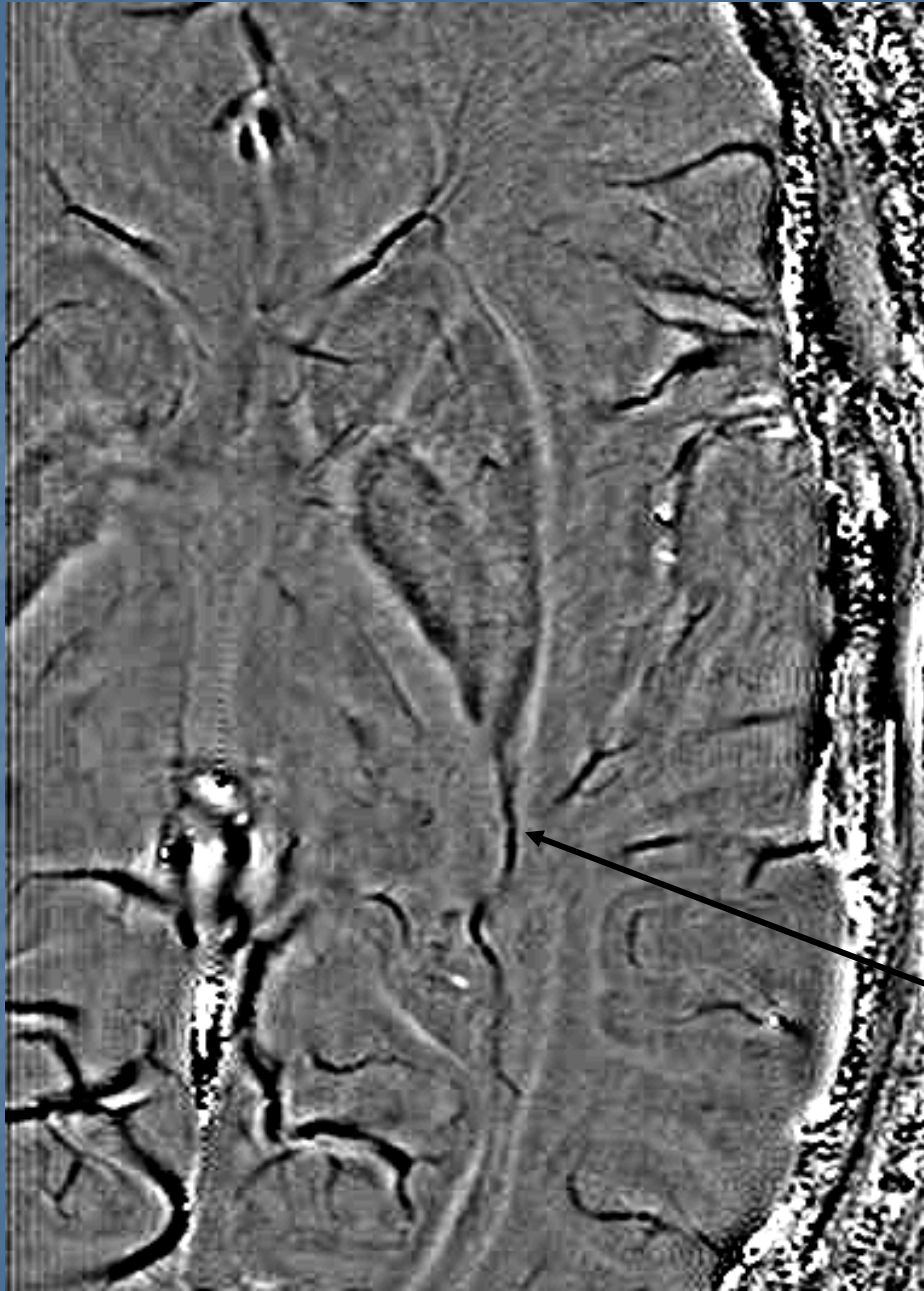
- Stroke
- Multiple sclerosis
- Tumor response
- fMRI
- Venous thrombosis

The Link Between Veins and Iron in Neurodegenerative Disease

Poor venous circulation can lead to vessel wall damage and microbleeding that increases over time.
Iron = hemosiderin



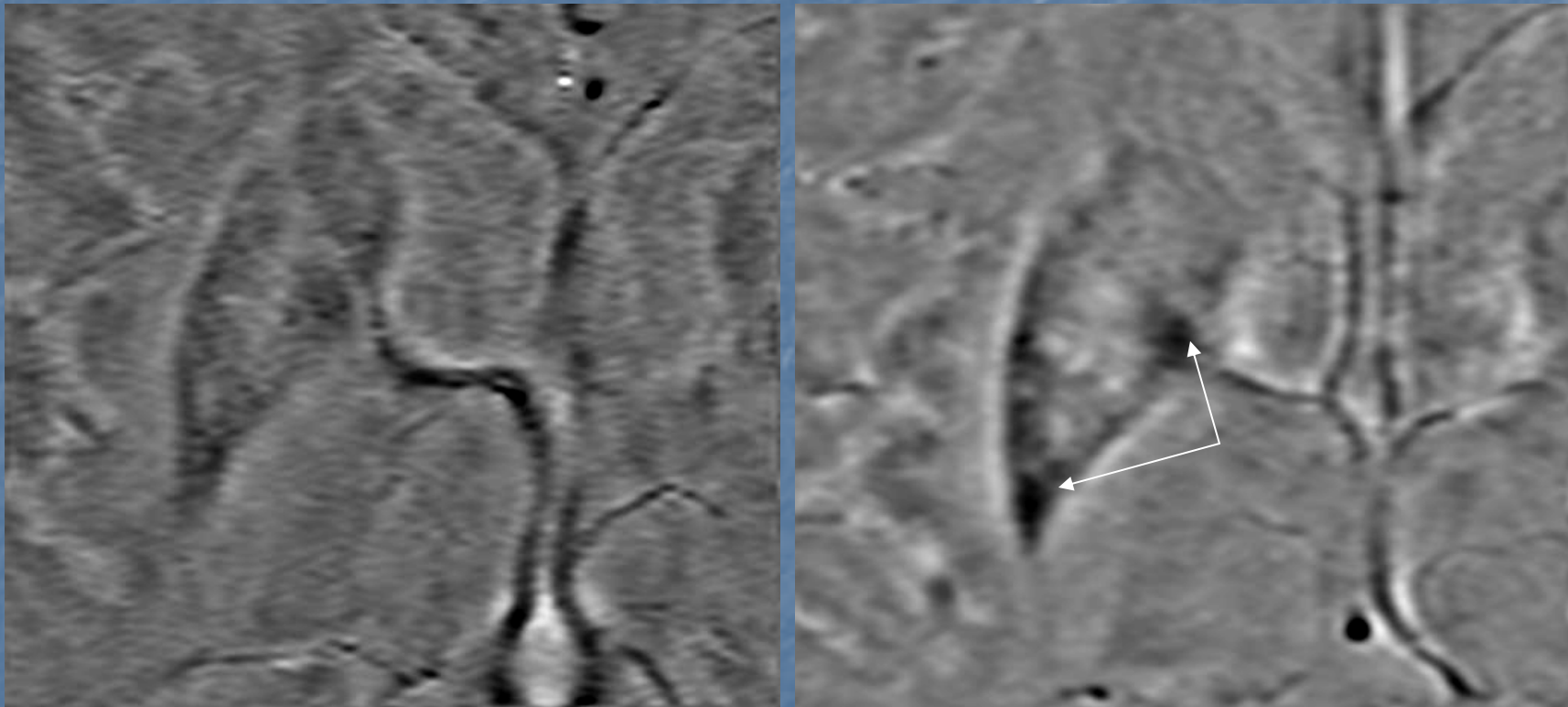
Caudate veins
and the
thalamostriate
venous
drainage
system as
seen with SWI
at 7T



Understanding iron build-up in the brain

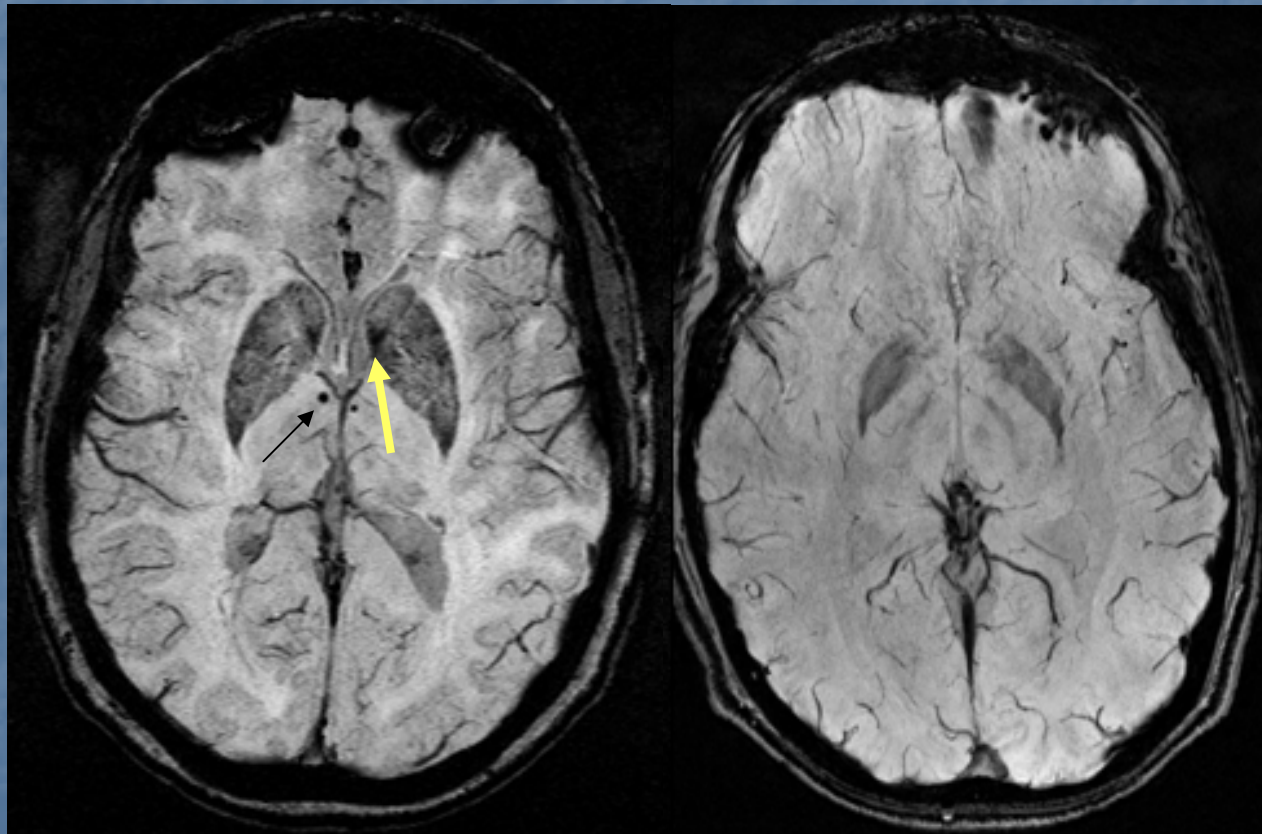
Draining vein from the
putamen may explain a
long term puzzle about
the pattern of iron build
up in the putamen

Caudate and Globus Pallidus



First insight: Could this change in phase be caused by blood vessels? Is it related to changes in iron content with age? Could it explain inter-subject variability?

CADASIL case for 50+ year old versus normal young volunteer



CADASIL

Young healthy subject

Iron in Multiple Sclerosis

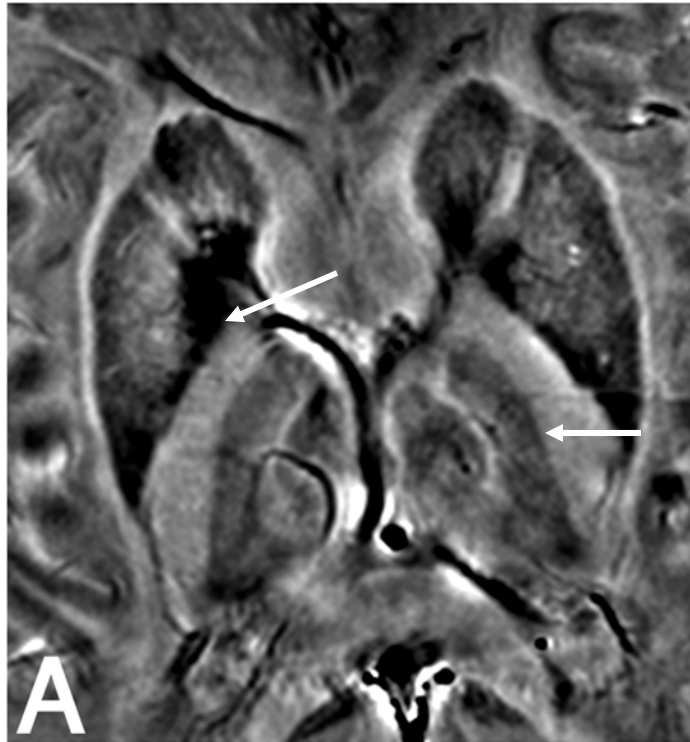


Figure A is from 10-10-2006

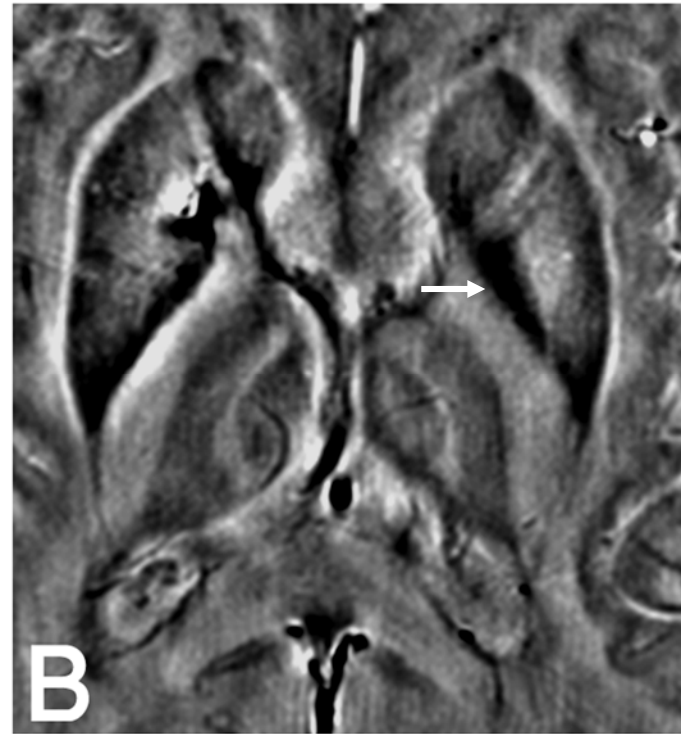
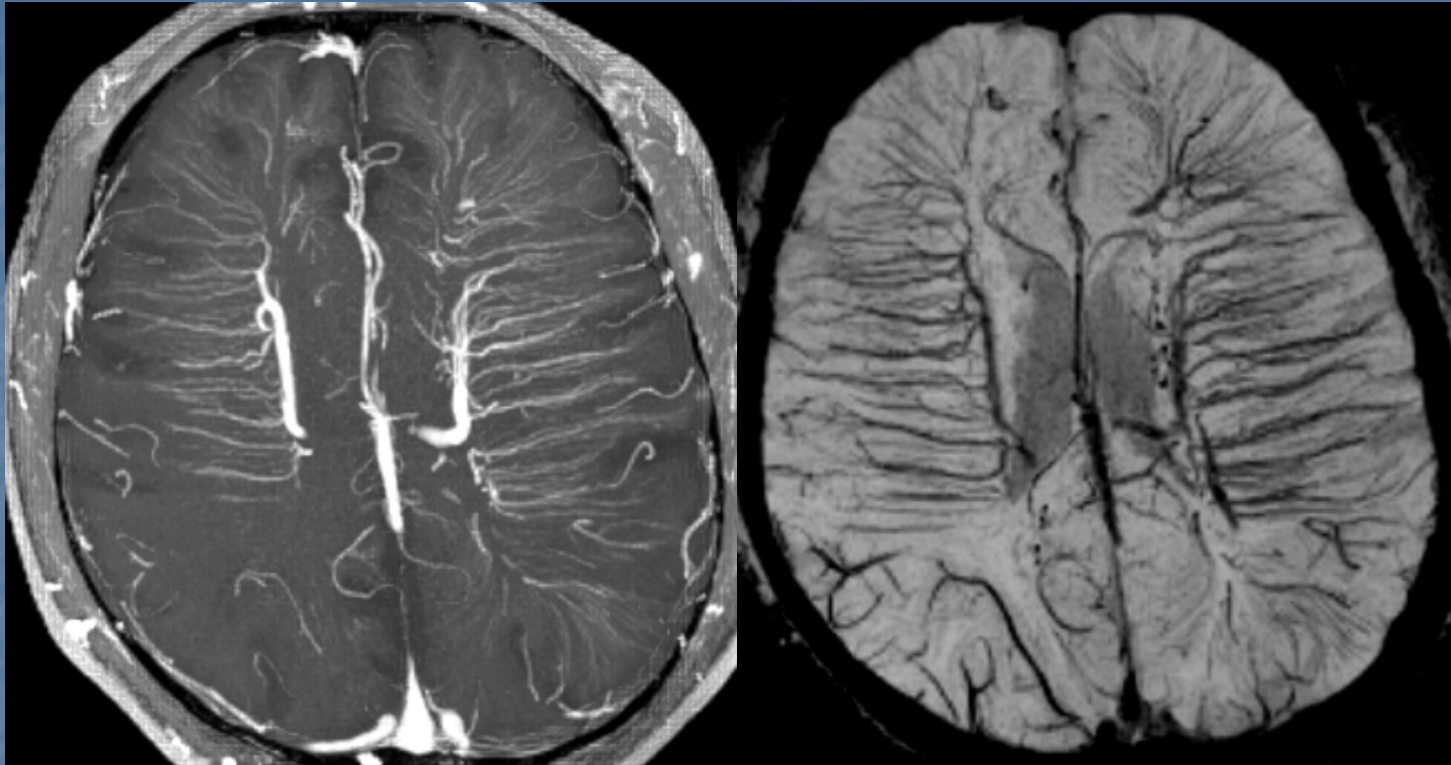


Figure B is from 3-25-2008



DVA: 39 year old woman presenting with recurring migraines – deep medullary veins draining into subependymal veins

Developmental venous anomaly similar to what we see in Sturge Weber disease:

Courtesy of Masahiro Ida

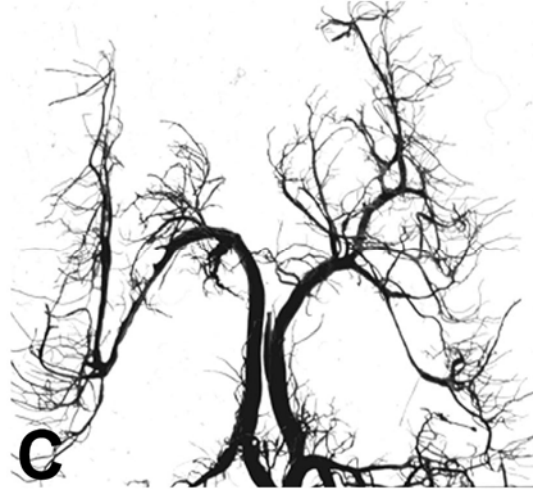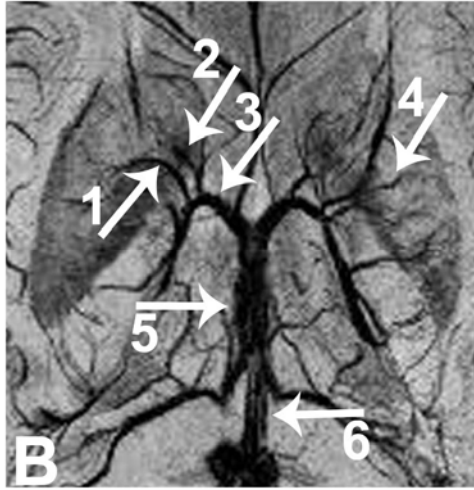
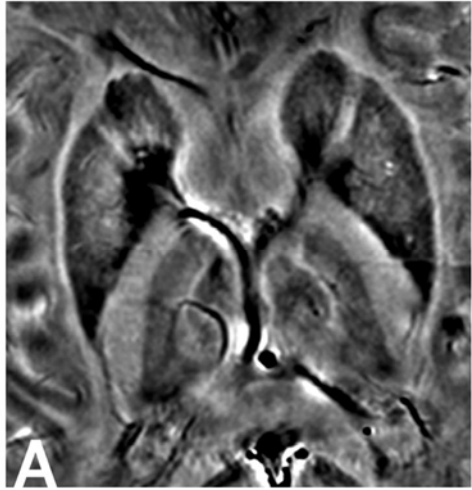
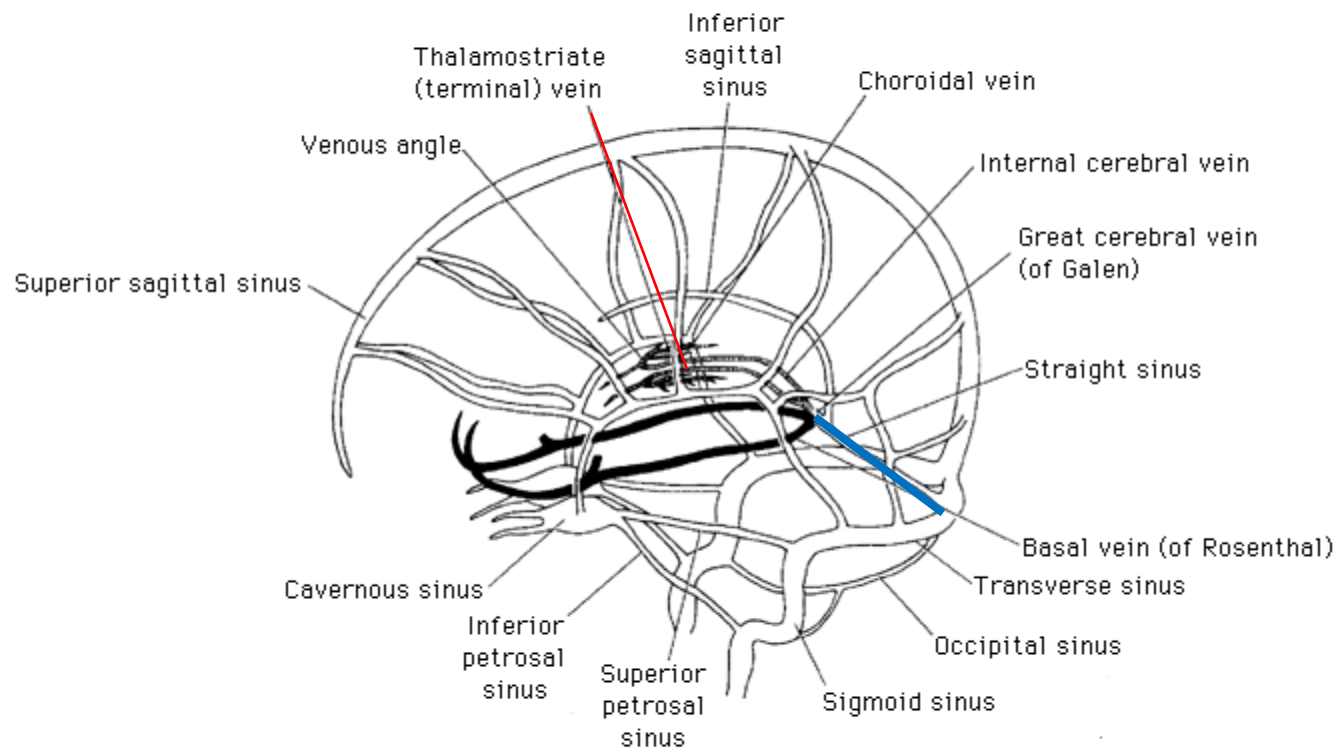
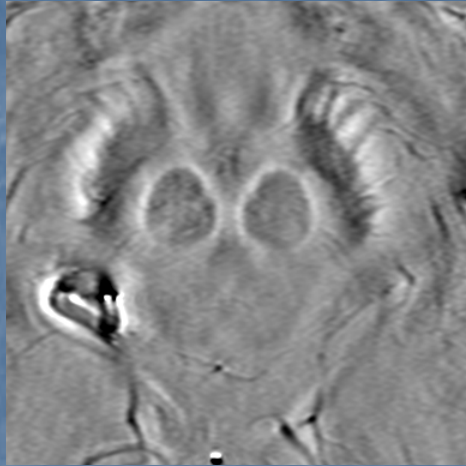


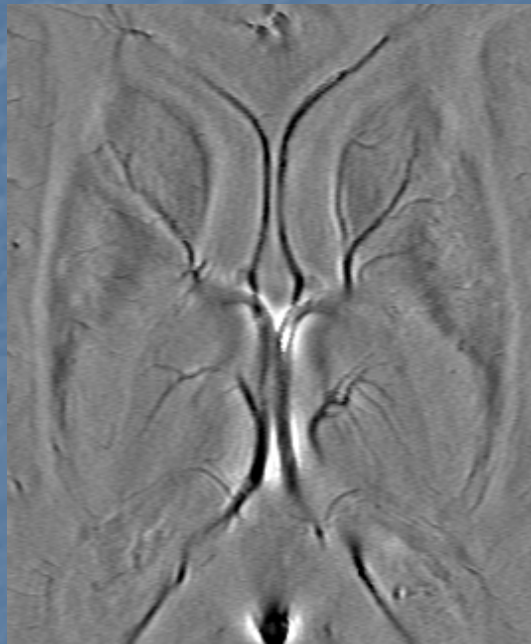
Figure 6. Major venous sinuses of the brain.



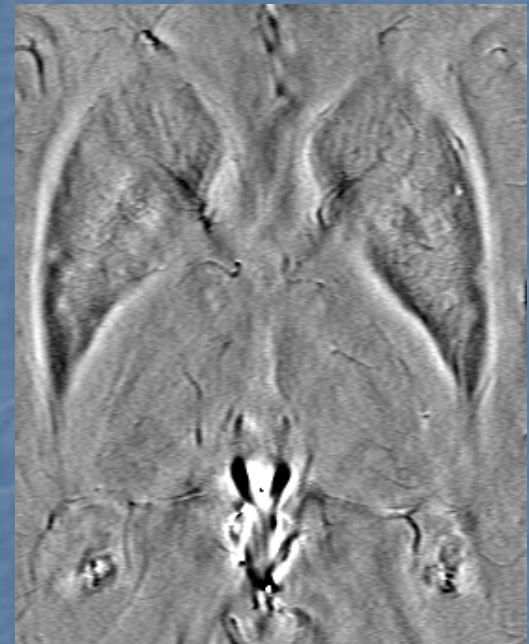Case 13



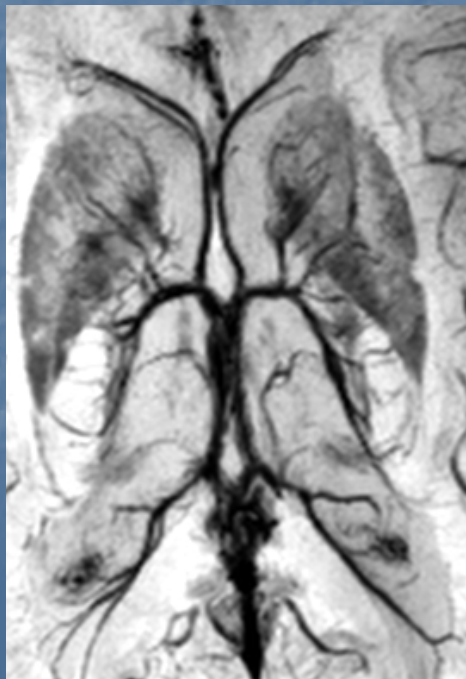
Midbrain



Thalamostriate System

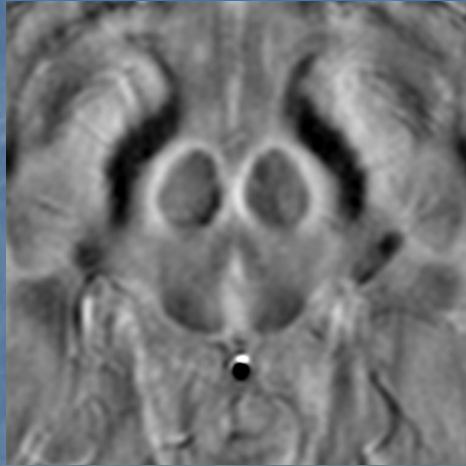


Basal Ganglia

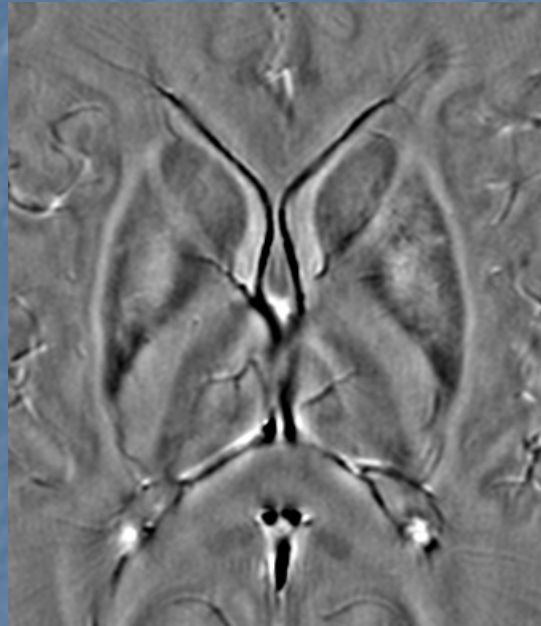


Thalamostriate system - mIP

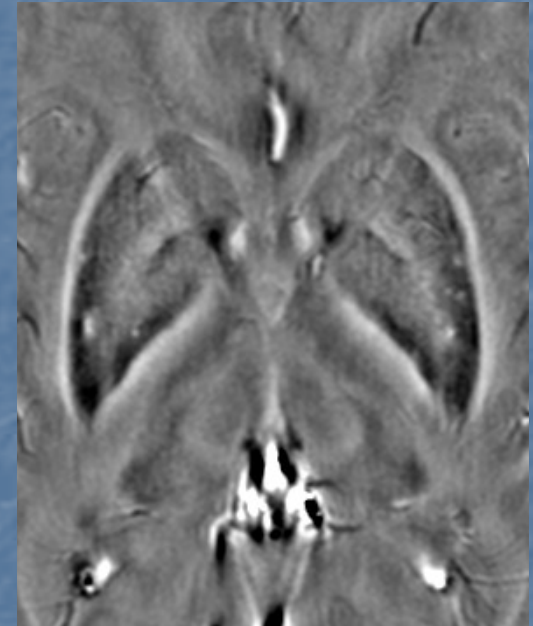
Case 5



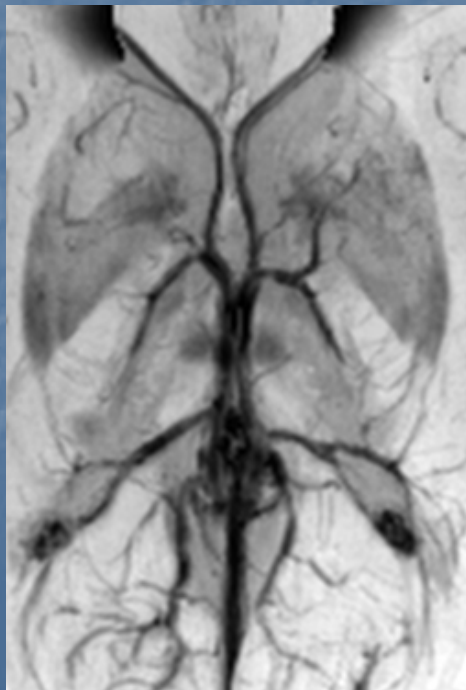
Midbrain



Thalamostriate System

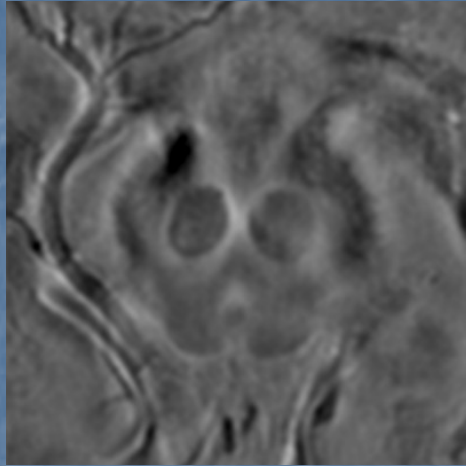


Basal Ganglia

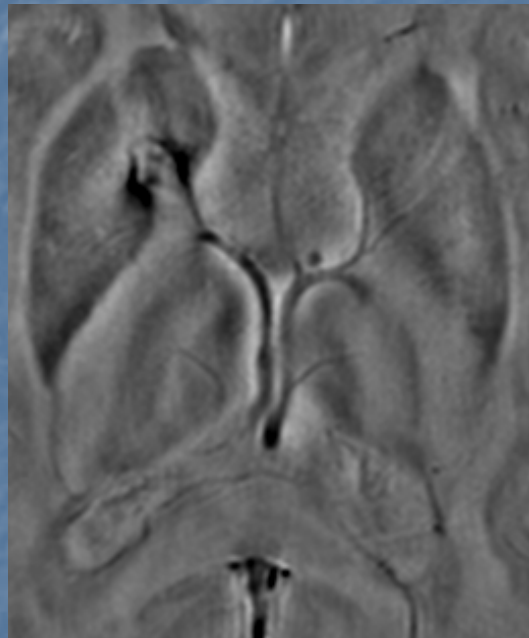


Thalamostriate system - mIP

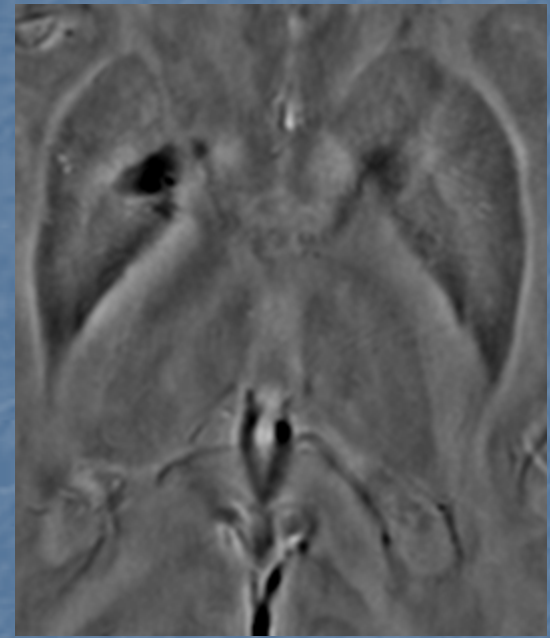
Case 6



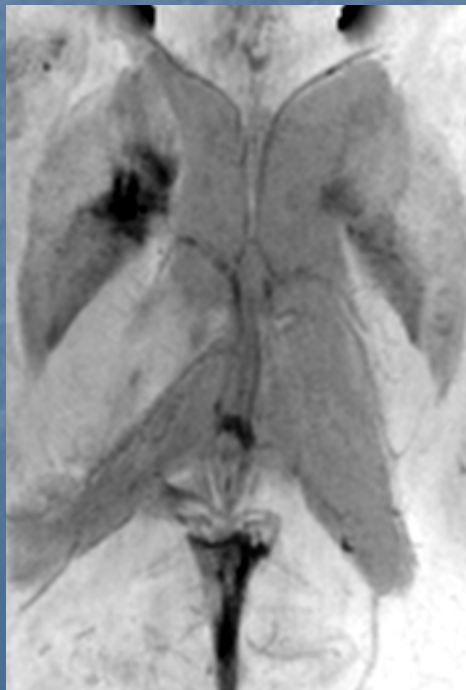
Midbrain



Thalamostriate System



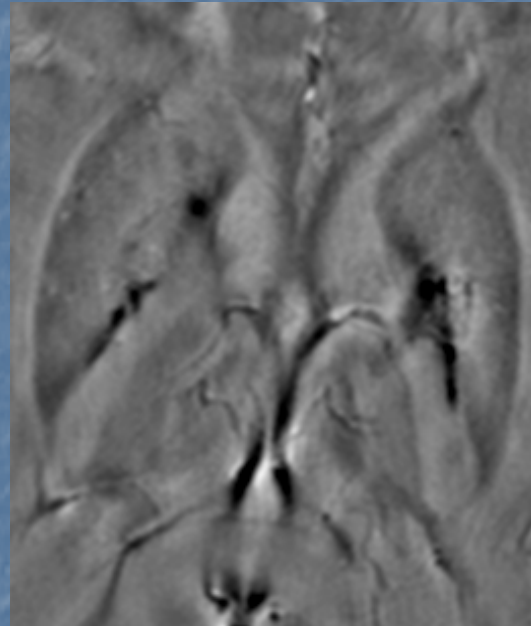
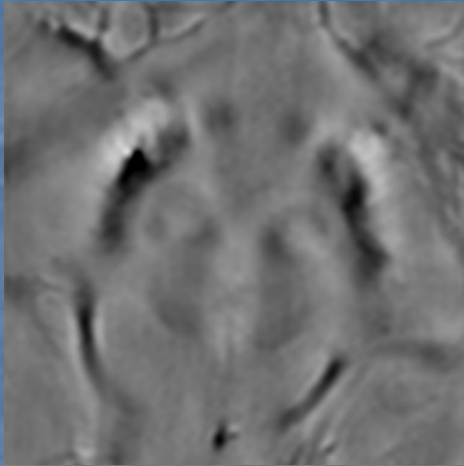
Basal Ganglia



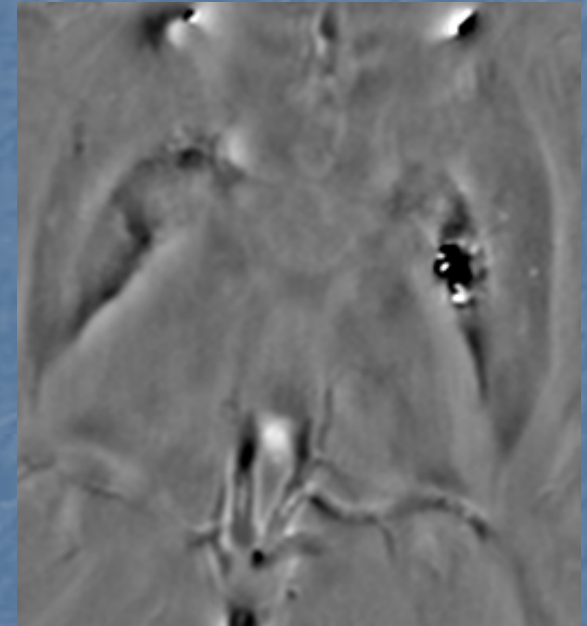
Thalamostriate system - mIP

Case 7

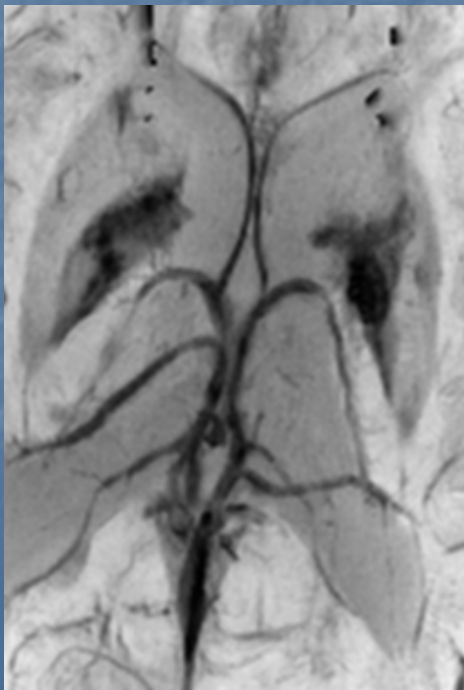
Midbrain



Thalamostriate System

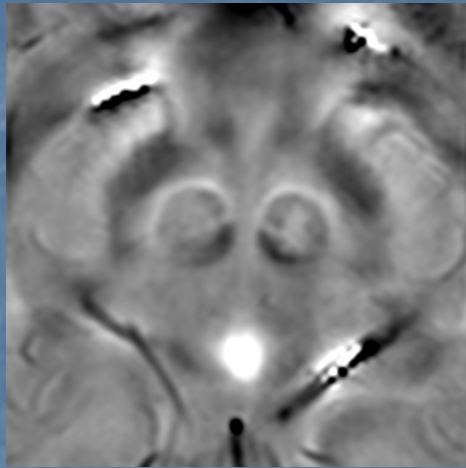


Basal Ganglia

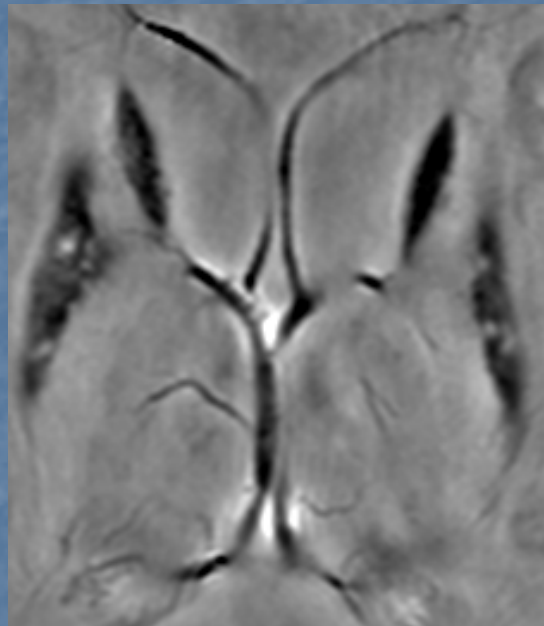


Thalamostriate system - mIP

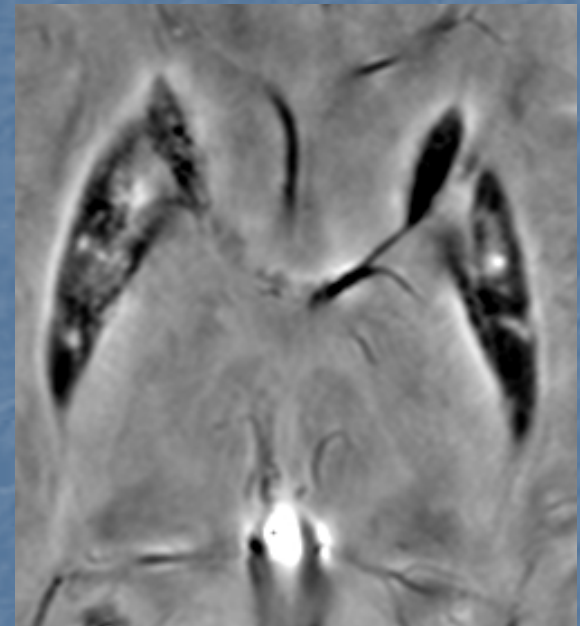
Case 11



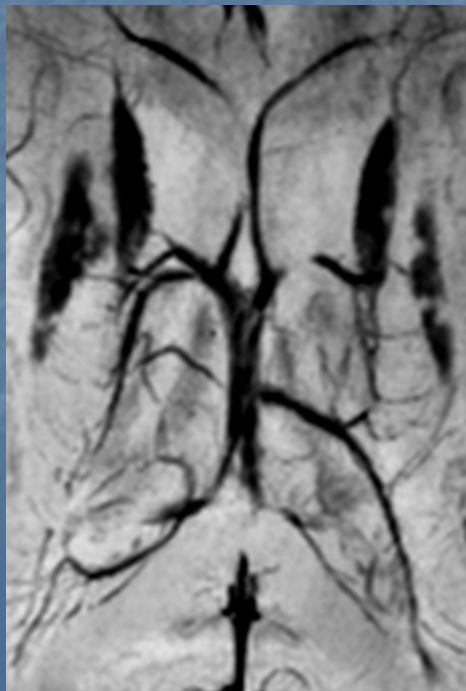
Midbrain



Thalamostriate System



Basal Ganglia



Thalamostriate system - mIP

High Iron Region (RII) - Total

RII - Total Iron								
PATIENT	CN	GP	PUT	PT	RN	SN	THA	Total
1				√				1
2	√			√				2
3								0
4	√	√	√	√			√	5
5		√		√	√	√		4
6						√		1
7								0
8				√		√		2
9	√		√			√		3
10				√		√		2
11								0
12								0
13								0
14			√			√		2
Total	3	2	3	6	1	6	1	9 out of 14

Inclusion of all regions

High Iron Region – Total
High Iron Region – Average
High Iron Region – Area
Whole Structure – Total
Whole Structure – Average

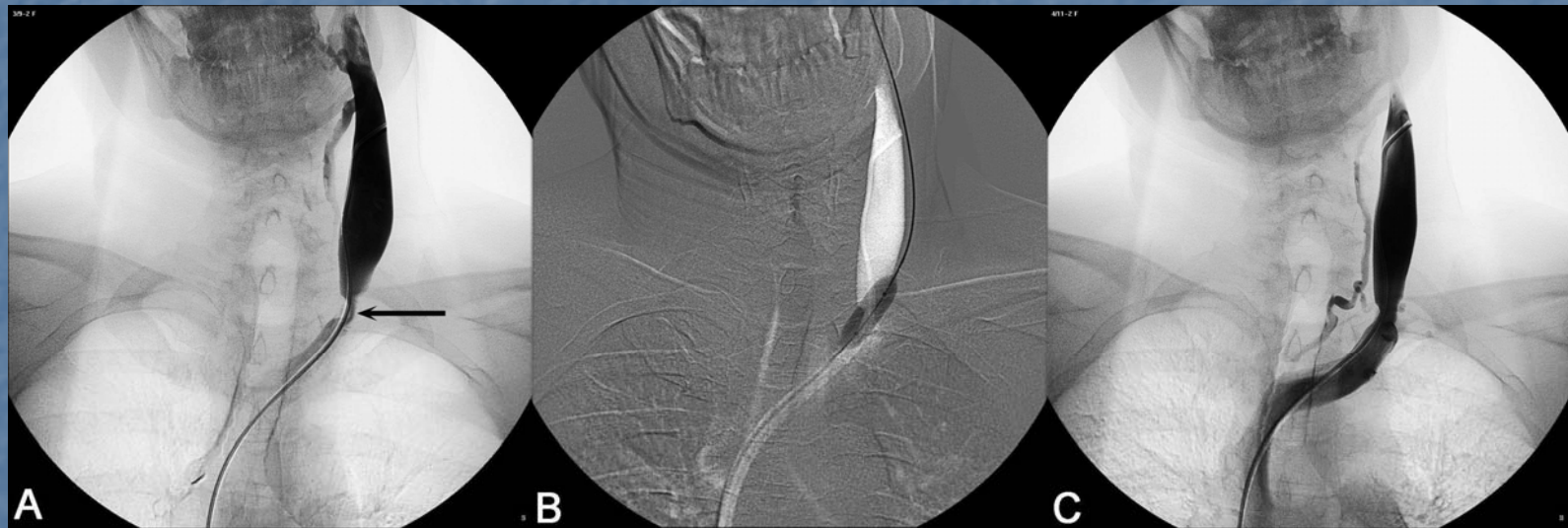All Measures

Iron that appears above average age matched values for any measure								
PATIENT	CN	GP	PUT	PT	RN	SN	THA	Total
1			√	√			√	3
2	√			√			√	3
3	√	√		√			√	4
4	√	√	√	√		√	√	6
5	√	√		√	√	√	√	6
6	√	√			√	√		4
7					√	√		2
8				√	√	√	√	4
9	√	√	√			√		4
10				√	√	√	√	4
11			√		√			2
12								0
13								0
14		√	√			√		3
Total	6	6	5	7	6	8	7	12 out of 14

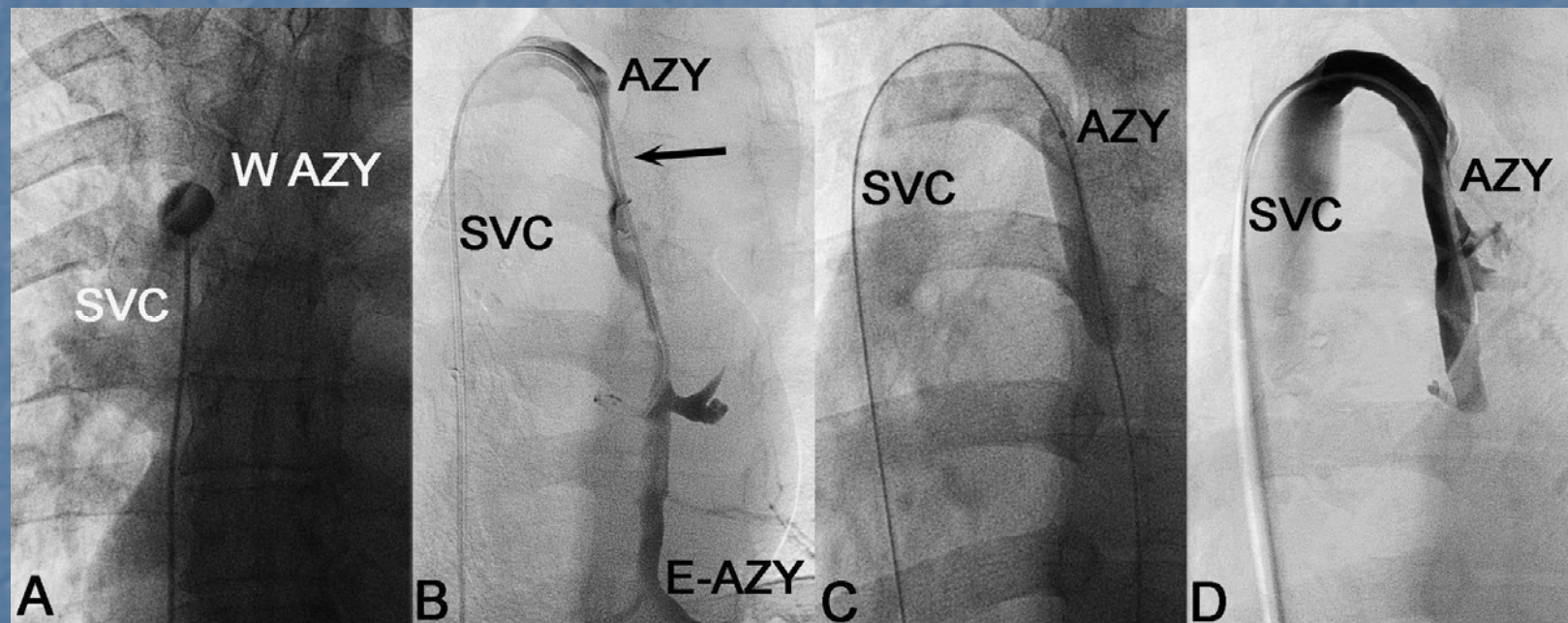
All Measures

Iron that appears above average age matched values for any measure								
PATIENT	CN	GP	PUT	PT	RN	SN	THA	Total
1			2	5			1	8
2	2			5			1	8
3	1	1		1			1	4
4	5	5	5	5		3	2	25
5	1	5	1	5	4	4	1	21
6	1	1			1	3		4
7					2	3		5
8				3	1	4	1	9
9	4	2	1			4		11
10				4	1	3	1	9
11			1		1			2
12								0
13								0
14		1	1			2		4
Total	6	6	5	7	6	8	7	12 out of 14

Paolo Zamboni and his team's proof



Paolo Zamboni and his team's proof

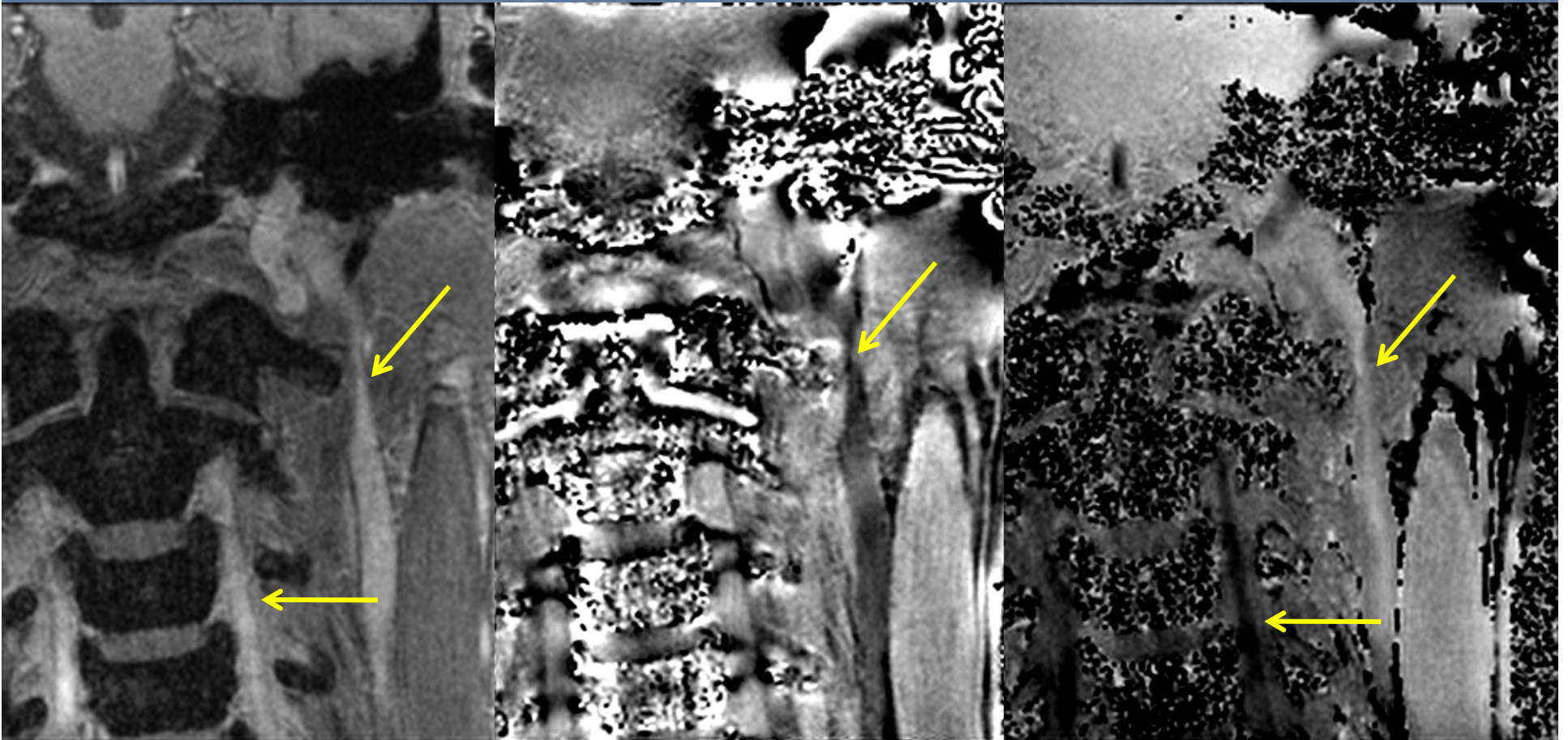


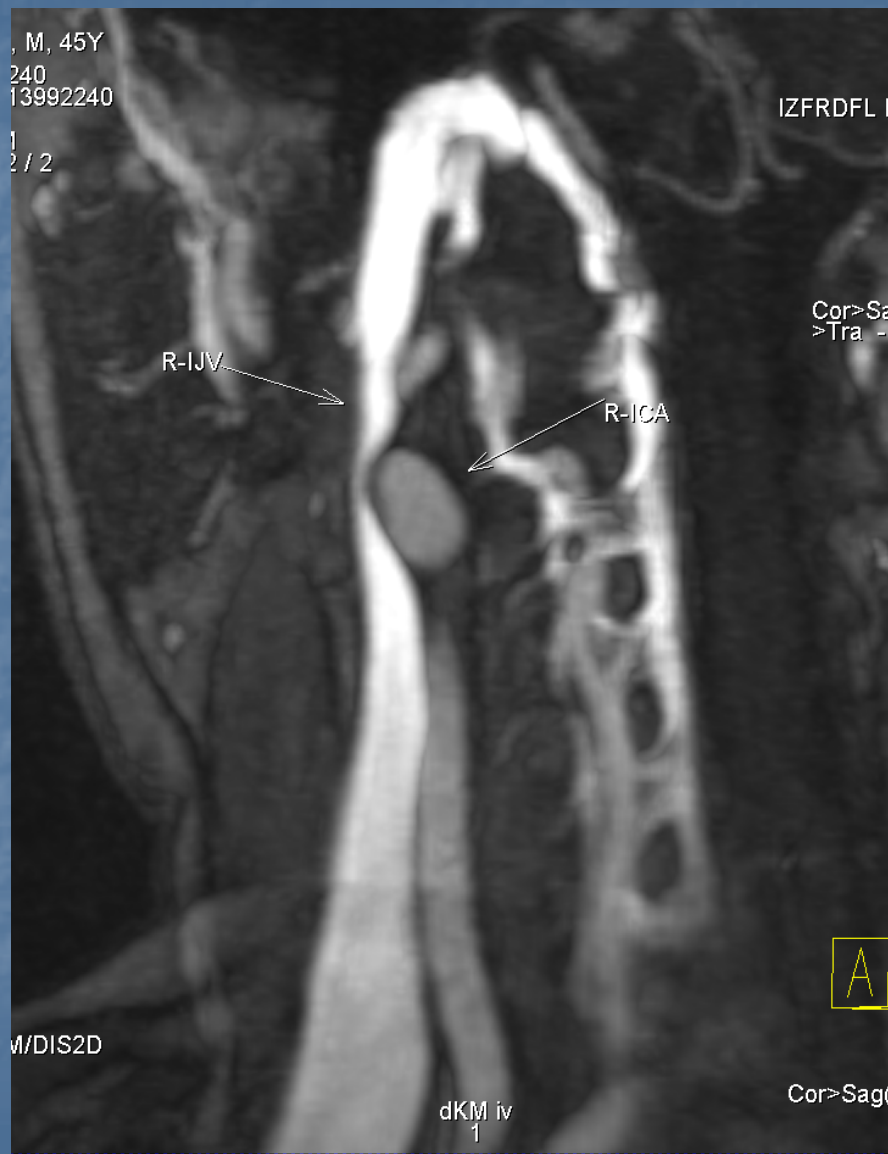
Our first case

Magnitude

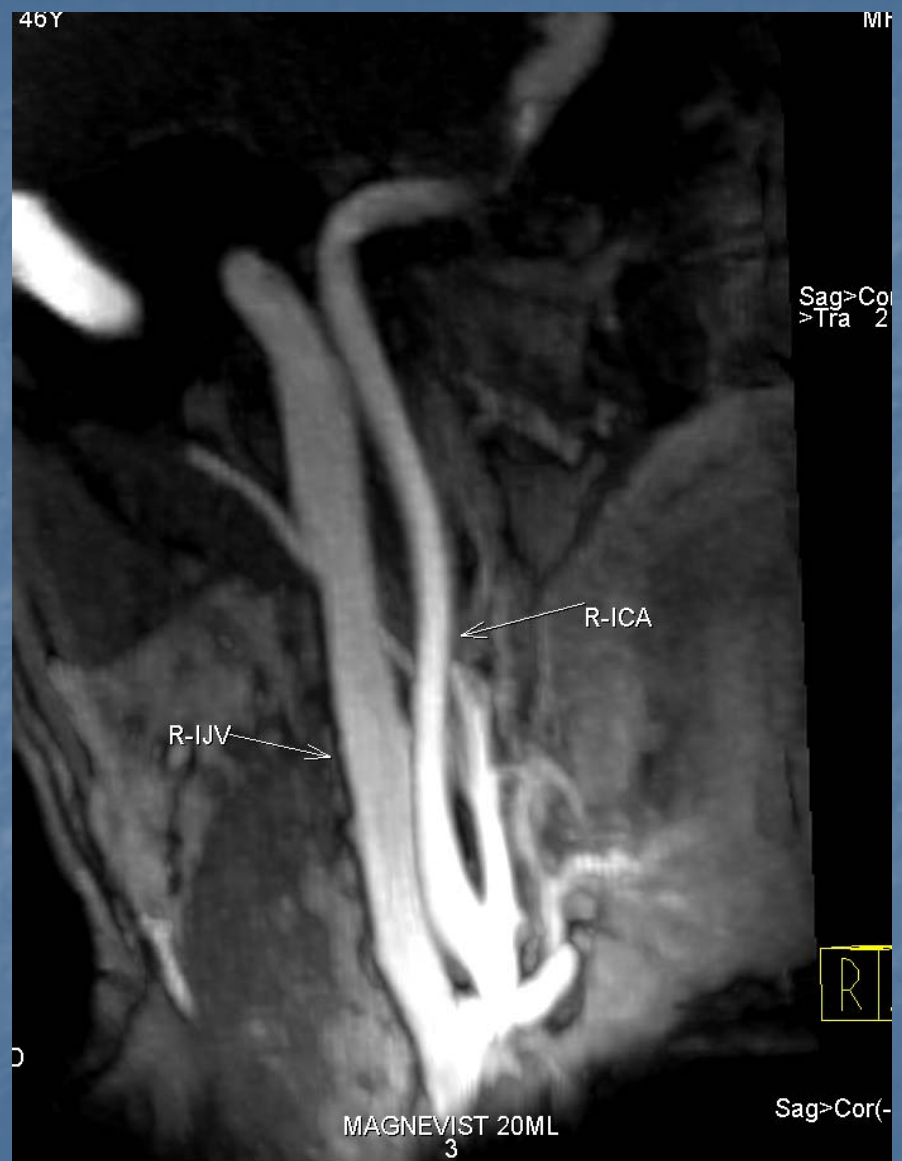Phase

Flow vertically



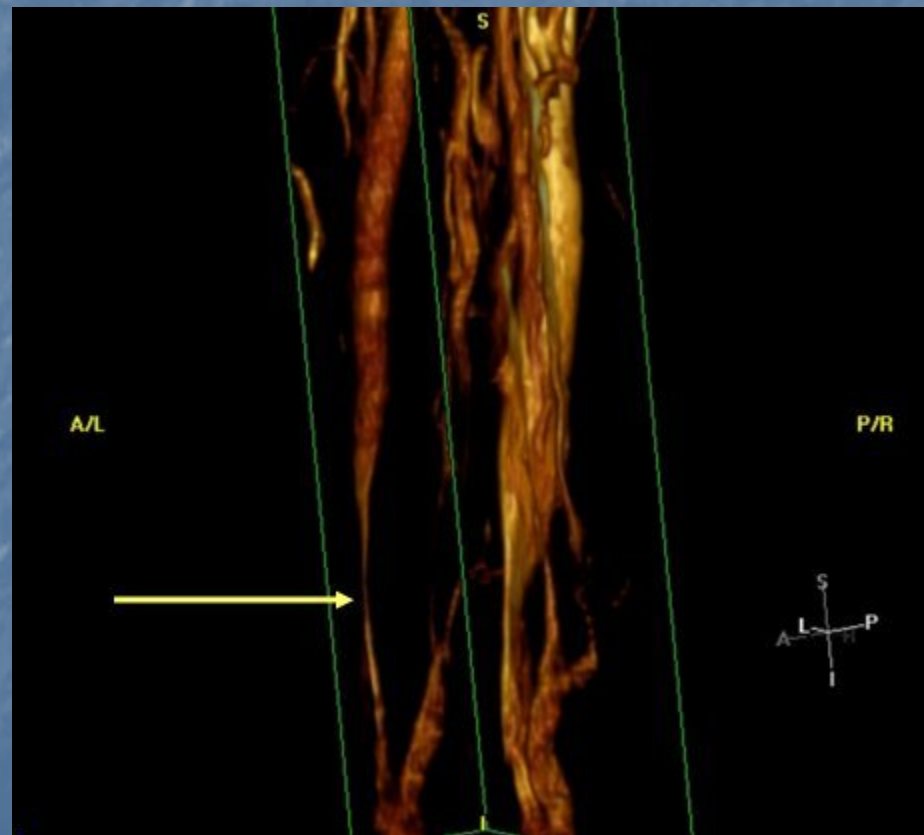


MS patient

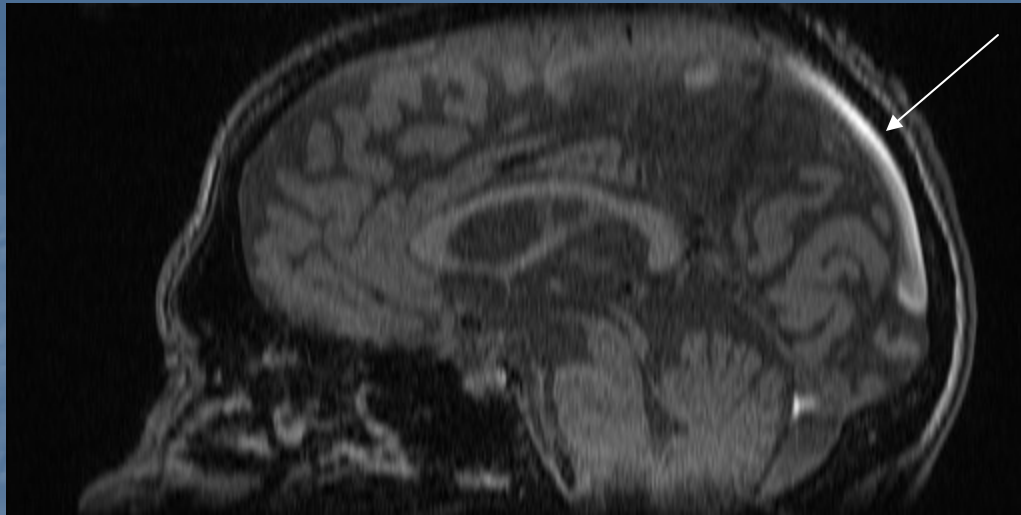


Normal control

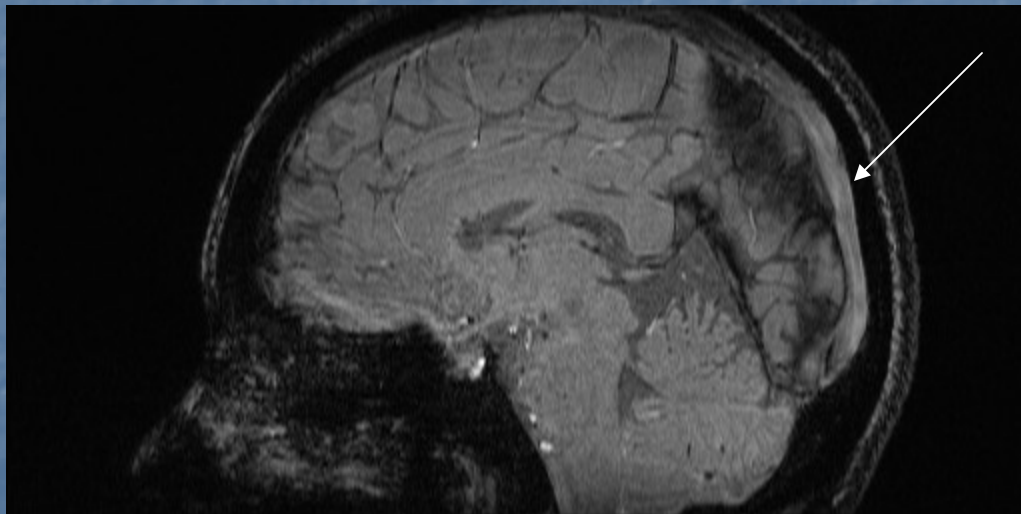
Example MRV data showing a tight stenosis in a young MS patient



3D MRV of narrowed vein



Abnormal
signal in the
sagittal sinus



Normal signal
in the sagittal
sinus

Implications of iron in multiple sclerosis

Ferritin in healthy tissue:
Nanomolars measured with SWI

Heme-iron for visualizing veins

- Vessel wall breakdown leads to microhemorrhage.
- Iron acts as an inflammatory agent exacerbating other effects of loss of vessel wall shear stress.
- Further breakdown of the microvascular system follows creating a pathology opposite to flow (just like Fog saw).
- Ischemic areas lose cerebral blood volume also from shunting of blood and atrophy of vessels.

Abnormal iron content in MS

Quantification of hemodynamics

Future Directions

- Can SWI iron content be used as a biomarker for venous vascular changes particularly in young patients?
- Does more iron indicate more severe tissue damage?
- Should we treat with anti-inflammatory and iron chelating agents?
- Does reperfusion put the vessels with now normal hemodynamics at risk because of vessel wall weakening?
- Can oxygen saturation and SWI measurements help demarcate the condition of local hemodynamics in the brain?

Conclusions

- MRI is a powerful means to collect 3D angiographic (both anatomical and functional) information and vessel wall information.
- SWI can be used for detecting deoxyhemoglobin as well as iron content in the form of hemosiderin or ferritin.
- MS patients have an increased amount of iron in the basal ganglia, and other basal ganglia structures.
- This may be from vascular damage to the veins in the form of hemosiderin or from ferritin from oligodendrocytes.

ADDENDA

We propose a simple first pass protocol to include the following three tests:

- ✓ *Post contrast time resolved MRA: to find the stenoses*
- ✓ *SWI: to find the iron and venous damage*
- ✓ *Flow quantification: to find the abnormal fluid dynamics*

Please visit our site www.nice-mri.com to review the database concept we are proposing and more importantly for MS updates starting Monday visit www.ms-mri.com

Short term future directions:

We are trying to collect as many cases as we can in the next few weeks in an open study so that I can take a proposal to some MS groups around the world to join us in this venture and share their data for a fixed protocol. *This work will be continued for the next few months to collect as many cases as possible.*

Long term goals:

Create a continuing database with a single international protocol for a blinded study in MS for patients with 10 years or less MS indications.

Collect hundreds of cases from sites around the world.

Research protocols could easily be tacked on to this such as 4D flow measurements, higher resolution SWI, etc but the baselines should stay the same for now. This would make all the work we do far more valuable to the medical community at large.